

Correlative assessment of BOLD MRI and Gleason Score in human prostate cancer - Preliminary Results

Rami R Hallac¹, Bishoy A Gayed², Qing Yuan¹, Ramy F Youssef², Yao Ding¹, Franto Francis³, Claus Roehrborn², Ganesh Raj², Robert D Sims¹, and Ralph Peter Mason¹

¹Radiology, University of Texas Southwestern Medical Center, Dallas, TX, United States, ²Urology, University of Texas Southwestern Medical Center, Dallas, TX, United States, ³Pathology, University of Texas Southwestern Medical Center, Dallas, TX, United States

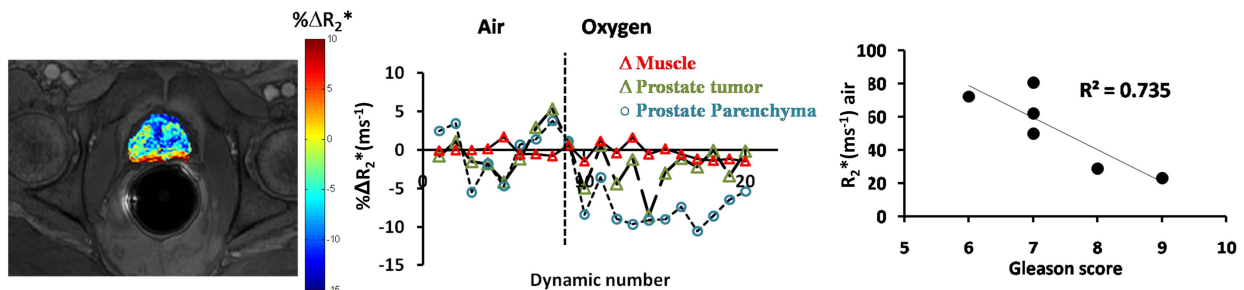
Target Audience: Radiologists, Urologists, Pathologists, Oncologists

Purpose: Prostate cancer remains the most common malignant tumor in men and hypoxia may be associated with a more aggressive phenotype (1,2). Oxygen sensitive MRI may provide insights into tumor characteristics and previous BOLD MRI studies have examined oxygenation of prostate cancer using carbogen (3,4), though it is not very well tolerated by patients. Here, we evaluated the changes in oxygenation of human prostate cancer in patients by oxygen breathing challenge using BOLD MRI and correlated observations with resected pathological specimen.

Methods: Following IRB approved consent ten men with biopsy confirmed prostate cancer (mean age 59 years, mean prostate-specific antigen (PSA) level 6.9 ng/mL and Gleason score ranged from 6 to 9) underwent BOLD MRI at 3T MR as part of their preoperative workup. Images were acquired using a 6-element SENSE body transmit coil and endorectal coil. Dynamic R_2^* maps were acquired using a multi-echo gradient-echo sequence, while subjects breathed air for 2 minutes followed by oxygen breathing challenge (15 l/min). Within 3 weeks following MRI, patients underwent robotic assisted laparoscopic prostatectomy. Analysis remains in progress for 4 patients.

Results: All patients tolerated BOLD MRI with oxygen challenge. Tumor location was identified based on histological findings. BOLD MRI revealed vastly different R_2^* values between patient prostates. R_2^* values ranged from 23.1 to 80.5 s^{-1} (mean = $52.8 \pm 23.2 s^{-1}$) and were found to be remarkably similar to the values of the surrounding normal prostate stroma ($R^2 > 0.92$, $p < 0.01$). By contrast surrounding muscle R_2^* values were very similar for all patients (mean: 55 ± 4.0 , range: 52 to 61.4), indicating that heterogeneous values were specific to each patient's prostate. Changes in BOLD response were heterogeneous in the tumor upon oxygen breathing (ΔR_2^* mean = $-1.6 \pm 1.4 s^{-1}$; range from -4.2 to $-0.4 s^{-1}$). No correlation was found between BOLD response and Gleason score; however, intriguingly a strong correlation was found between baseline R_2^* rates and Gleason score ($R^2 > 0.73$; $p < 0.05$).

Conclusion: BOLD MRI with oxygen challenge was well tolerated in patients and found to be a feasible noninvasive addition to a routine scan. We believe these preliminary results warrant further testing as to how R_2^* and its response to oxygen-breathing challenge correlate with location, pathology, and potentially staging of tumors.



BOLD kinetics in prostate tumor and stroma for a representative patient Left: Color map showing the R_2^* change accompanying 100% oxygen. Center: R_2^* response ($\% \Delta R_2^*$) of tumor, prostate stroma and muscle to breathing O_2 . Right: Correlation of baseline R_2^* and Gleason score.

References: (1) Turaka, A, et al.; *Int. J. Radiat. Oncol. Biol. Phys.*, 82; E433-E439 (2012); (2) Tatum, JL, et al.; *Int. J. Radiat. Biol.*, 82; 699-757 (2006); (3) Chopra, S, et al.; *Int. J. Radiat. Biol.*, 85; 805 - 813 (2009)(4) Alonzi, R, et al.; *Br J Cancer*, 100; 644-648 (2009)