

Pre-Operative Evaluation of Patients Undergoing Knee Articular Cartilage Defect Repair: MRI Thickness Maps Derived from a Validated, Automated Segmentation Platform - Initial Results

Joshua Farber^{1,2}, Jose Tamez-Pena³, Saara Totterman⁴, Bruce Holladay⁵, Forest Heis⁵, John Larkin³, and Michael Greiwe⁵
¹Radiology, Radiology Ass of N KY, Cincinnati, Ohio, United States, ²Imaging, Qmetrics, Rochester, NY, United States, ³Mathematics and Statistics, Tec de Monterrey, Monterrey, NL, Mexico, ⁴Qmetrics, Rochester, NY, United States, ⁵Orthopedic Surgery, Commonwealth Orthopaedic centers, Edgewood, KY, United States

OBJECTIVE: To present a robust, automated methodology that generates 3D articular cartilage (AC) thickness maps of the knee, and which delineates the size and location of AC Defects, as well as the thickness and integrity of the defect walls, to serve as an accurate pre-operative guide for AC defect repair.

METHODS: A sagittal 3D FSE FS sequence (TR- 2300, TE - 20) is obtained on all patients undergoing routine 1.5T MRI (Optima 450W, GE, Milwaukee) of the knee at our facility. These 3D FSE data sets are sent to a dedicated work station (Qmetrics Technologies, Rochester, NY), which automatically segments the articular cartilage. The segmented images are then reviewed by a radiologist for accurate fit with the source images. If necessary, edits can be made on the dedicated work station to ensure proper segmentation. The methodology of this process has been validated (1). From the segmented data sets, 3D AC thickness maps are generated automatically. These thickness maps are then reviewed by the radiologist for accuracy, compared to the source images. In patients who underwent subsequent AC defect repair, intra operative measurements and images were obtained of the AC defect size and location. The intra operative, gold standard data were then compared with the prospectively obtained thickness maps to assess the accuracy of lesion size and location depiction.

RESULTS: Initial results (N=12) validate the accuracy of the thickness maps in delineating AC defect size and location (Figure 1). In addition, the thickness maps accurately depict the thickness and integrity of the AC defect walls, allowing for accurate surgical debridement and pre-operative planning for graft material allocation. In no case to date did a thickness map miss an AC defect of the segmented regions.

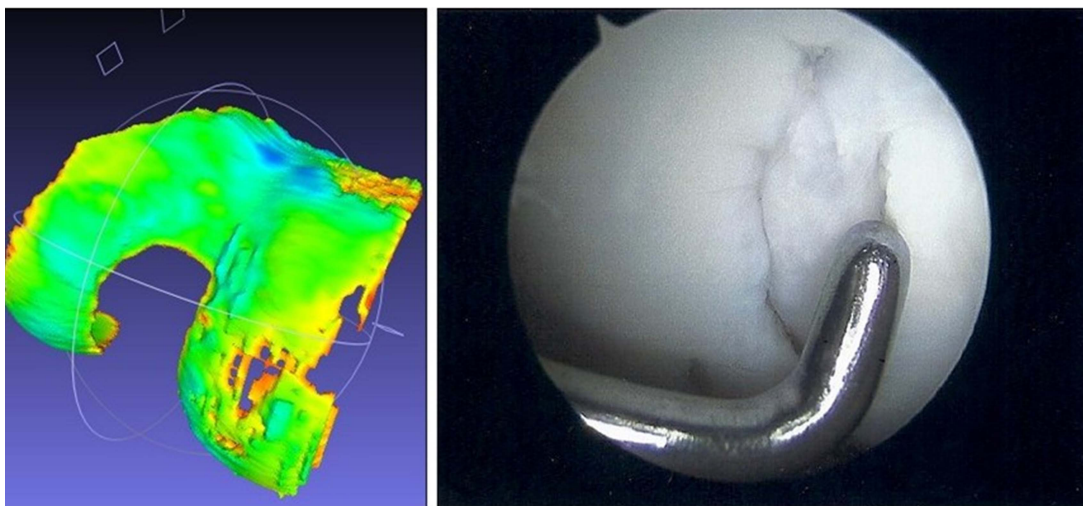


Figure 1: Pre – Operative Thickness Map shows large AC defect of the medial femoral condyle, confirmed at surgery.

Conclusion: In our initial experience, 3D AC thickness maps accurately detect AC defects, and accurately delineate lesion size and location, as well as the integrity of the AC defect wall, and a clinically useful pre-operative tool. In addition, these automatically generated 3D maps can be displayed along any axis, and serve as a useful tool for physician-patient interactions when discussing treatment options. Further work is required to obtain statistical validation. Further work will include also the use of T2 maps (2,3), with the thickness maps serving as a template, to further assess defect wall integrity, to optimize further intra-operative debridement and graft material allocation.

References: 1) Unsupervised Segmentation and Quantification of Anatomical Knee Features: Data From the Osteoarthritis Initiative. Tamez-Pena, J, et al. IEEE Transactions on Biomedical Engineering; April 2012; Vol 59; No 4; pp 1177-1186. 2) MR Imaging and T2 Mapping of Femoral Cartilage. Goodwin, D, et al, AJR; 2001; 177; pp 665-669. 3) Magnetic Resonance 3D FSE Technique in the Knee: Bridging Clinical and Research Imaging. Farber, JM, et al. ICRS Newsletter, Special Focus: Imaging 2012; Vol 15;pp23-24.