

Visual Assessment of Cartilage Degeneration by 3D Cartilage T2 Map -Comparison with Arthroscopic Findings-

Satoru Tamura¹, Takashi Nishii¹, Hidetoshi Hamada¹, Ken Nakata¹, Tatsuo Mae¹, Hisashi Tanaka¹, and Hideki Yoshikawa¹

¹Osaka University Graduate School of Medicine, Suita, Osaka, Japan

Target audience

Target audiences of this study are radiologists and orthopaedic surgeon related to arthroscopic surgery in the knee joint.

Purpose

Magnetic resonance (MR) imaging is one of the effective non-invasive methods to investigate the cartilage degeneration. Recent studies showed cartilage T2 value is closely related to cartilage collagen matrix and water content, with significant correlation between higher T2 values and cartilage degenerative changes [1, 2]. Our previous study revealed characteristic 3D distribution of T2 values in the femoral cartilage of healthy volunteer knees by using 3D T2 map, and suggested this technique was useful for global and local assessment of the whole femoral cartilage [3]. However, it has not been revealed whether cartilage damage can be detected reliably on knee 3D T2 maps. The purpose of this study was to compare the diagnosis of cartilage degeneration by 3D reconstructed T2 mapping with arthroscopic findings.

Methods

Thirty-four patients who underwent knee arthroscopic surgeries were included in this study. There were 24 males and 10 females, and the mean age was 31.4 years (range; 13 to 59 years). MR imaging of patients were performed one day before surgery. Sagittal 3D-FIESTA-C images (TR/TE:12.7/6.3ms; slice thickness: 1.5mm; FOV: 12 cm; acquiring time: 10min27sec.) and 2D consecutive sagittal T2 map images (TR: 1500 ms; TE: 8 echoes between 10- 80 ms; slice thickness: 3 mm; FOV: 12 cm; acquiring time: 12min54sec.) were obtained using 3.0-T MRI system (GE Healthcare).

After the 3D cartilage and meniscus models was reconstructed from the images of 3D-FIESTA-C, T2 color map was laid on the 3D model using custom-made software (Baum globe, Osaka Univ.) (Figure 1). The whole femoral cartilage was divided into 5 region of interests (ROIs) as anterior zone (Zone A), weight bearing zone covered by meniscus in lateral condyle (Zone WL), weight bearing zone covered by meniscus in medial condyle (Zone WM), posterior zone in lateral condyle (Zone PL) and posterior zone in medial condyle (Zone PM) (Figure 2).

The color map reflecting T2 value was calibrated with the minimum and maximum values determined according to previous investigations of normal volunteers [3]. Presence or absence of cartilage degeneration was analyzed in each zone by using full thickness mapping and superficial layer mapping, as lesions defined when T2 value increased locally (blue lesion) on the 3D T2 map. Image diagnosis was conducted analyzed by 2 orthopaedic surgeons who did not know patients' history.

Cartilage damage was classified 3 grades depending on arthroscopic findings as no degeneration (G0), superficial degeneration (G1) including softening, fissuring and shallow erosion, and deep degeneration (G2) including deep erosion, flap and defect. After surgery, the grade of cartilage degeneration in each zone was recorded by operators.

The image diagnosis was compared with the arthroscopic findings and the sensitivity and specificity were calculated in each zone.

Results

There were 42 zones with cartilage degeneration in all patients. In all 170 zones examined, the sensitivity was 70% and the specificity was 88%. The sensitivity and the specificity were 80% and 93% in Zone A, 69% and 67% in Zone WL, 68% and 100% in Zone WM, respectively. The specificity was 97% in Zone PL and 83% in Zone PM (Table 1). There were 26 zones with G1 damage and 16 zones with G2 damage. Fourteen zones (54%) in G1 damage and 12 zones (75%) in G2 damage were detected by image diagnosis.

Discussion

MR imaging is useful method to detect the cartilage abnormalities. There were many reports that compared MR imaging with arthroscopic findings about morphological cartilage abnormalities [4]. However, there were few reports that compared MR imaging with arthroscopic findings about quantitative cartilage abnormalities. The sensitivity and the specificity were 70% and 88% in all zones and were 68% - 80% and 67% - 100% in each zone. These results were within acceptable range.

In this study, the color bar for 3D T2 maps was set between 15ms and 75ms with blue lesion demonstrated at T2 value of 60ms or more, according to the previous examinations of normal subjects. Normal range of knee cartilage T2 values may differ according to ages of subjects. Additional studies to optimize definition of the color bar for each subject are important to obtain more accurate diagnostic ability of 3D T2 cartilage mapping.

In conclusion, 3D T2 map was useful to detect the cartilage degeneration visually and locally.

References

- [1] Chou MC. Osteoarthritis Cartilage 2009; 17: 441-447
- [2] Menezes NM. Magn Reson Med 2004; 51: 503-509
- [3] Shiomi T et al. Skeletal Radiol. 2012; in press
- [4] Quatman CE. et al. Am J Sports Med. 2011; 39: 1557-1569

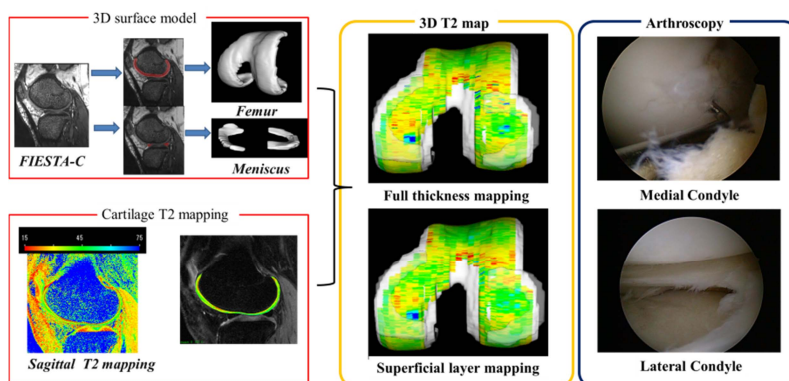


Figure 1 Reconstruction of 3D T2 map

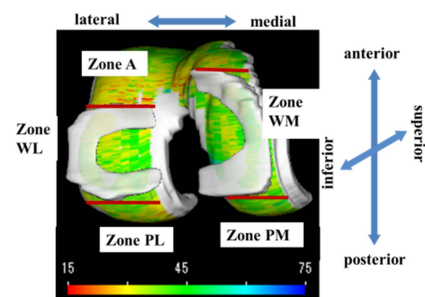


Figure 2 Definitions of ROIs

Table 1 The sensitivity and the specificity in each zone

	sensitivity	specificity
All zones	70%	88%
Zone A	80%	93%
Zone WL	69%	67%
Zone WM	68%	100%
Zone PL	N/A	97%
Zone PM	N/A	82%