

Cervical Spine DWI using Reduced-FOV Multi-shot EPI with 2D Phase Cycling Reconstruction

He Wang¹, Chao Ma², Nan-Kuei Chen³, Jianping Lu², Allen Song³, and Guang Cao¹

¹MR Research China, GE Healthcare, Shanghai, China, ²Department of Radiology, Changhai Hospital, Shanghai, China, ³Duke University Medical Center, Durham, NC, United States

Introduction: Diffusion-weighted (DW) imaging is one of the most powerful tools for detecting lesions because it can assess the microscopic mobility of water molecules and get quantitative information without the use of contrast media. DWI data are commonly acquired with commercial available single-shot echo-planar imaging (SS-EPI) sequence. However, SS-EPI is not widely used for DWI of the cervical spine, because of the magnetic field inhomogeneities around the spine and the increased motion in that area due to breathing and swallowing. These result in artifacts with the usually long readout duration of the ss-EPI method. To overcome this shortcoming, reduced FOV Single-shot DW-EPI[1] was proposed, in which a 2D spatially selective echo-planar RF excitation pulse reduced the FOV in the phase-encode (PE) direction. Multi-shot DW-EPI is another effective way that can reduce distortion but suffers from the severe phase error from odd and even PE lines and from different shots. Recently, a 2D phase cycling reconstruction method[2] was developed to reduce the phase error without the time consuming 2D reference scan. In this study, we tried to combine the reduced FOV and 2D phase cycling Multi-shot methods together to improve the DW image quality of cervical spine.

Methods: This study was performed on a 3.0-T scanner (Signa HDxt, GE Healthcare, Milwaukee, WI) with an eight-channel NV-array coil. Four sets of DW images were acquired in the sagittal orientation from one healthy volunteer. All the diffusion-weighted images were acquired in three mutually orthogonal diffusion encoded directions using the following parameters: 1) **Full-FOV Single-shot (FFSS) DWI:** FOV 240 x 240 mm², matrix 64 x 64, thickness 4 mm, NEX 4, B-value 500 s/mm², TR 2000 ms; 2) **Reduced-FOV Single-shot (RFSS) DWI:** 2D-RF excited, FOV 240 x 96 mm², matrix 160 x 64, thickness 4 mm, NEX 4, B-value 500 s/mm², TR 2000 ms; 3) **Full-FOV 4-shot (FF4S) DWI:** 4-shot, FOV 240 x 240 mm², matrix 160 x 160, thickness 4 mm, NEX 4, B-value 500 s/mm², TR 2000 ms; 4) **Reduced-FOV 4-shot (RF4S) DWI:** 2D-RF excited, 4-shot, FOV 240 x 96 mm², matrix 160 x 64, thickness 4 mm, NEX 4, B-value 500 s/mm², TR 2000 ms. The P files of 4-shot images were saved and the 2D phase cycling reconstruction was performed offline in MATLAB.

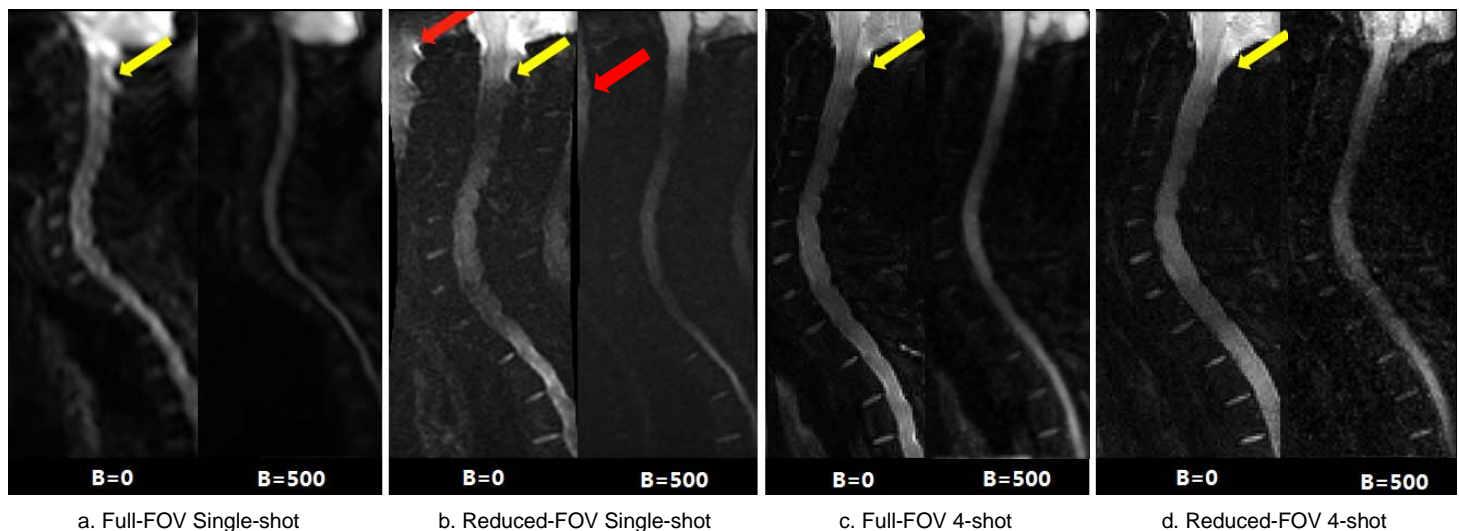


Fig. 1 Four sets of DW images with different scan parameters

Results and discussion: The images of the central slice with four different protocols are shown in Fig 1. Obviously, the resolution of all the images except FFSS (Fig.1a) is high enough for clinical use and the Nyquist artifacts (red arrows) are removed perfectly by the 2D phase cycling reconstruction (Fig. 1c and d). We can also find out that the distortions in CSF (yellow arrows) are reduced most in RF4S (Fig.1d), however, the SNR of RF4S is lower than FF4S because of the smaller FOV. The scan time of single-shot and 4-shot DWI was 32s and 2 min 8s respectively. For comparison, we used same NEX for both full and reduced FOV. Actually, the NEX could be doubled to increase the SNR of RF4S while the scan time is a little more than 4 min which is still clinically acceptable.

Conclusion: The reduced-FOV multi-shot EPI with 2D phase cycling reconstruction can be an effective way to improve the DW image quality of cervical spine..

References: [1] Saritas EU, et al., MRM. 2008; 60:468-473. [2] Chen NK, et al., MRM. 2011; 66:1057-1066