

MRI of Fat Content in the Abdomen and Liver of Obese Mice Following Vertical Sleeve Gastrectomy

Patrick Winter¹, Andriy Myronovych², and Rohit Kohli²

¹Radiology, Cincinnati Children's Hospital, Cincinnati, OH, United States, ²Gastroenterology, Hepatology and Nutrition, Cincinnati Children's Hospital, Cincinnati, OH, United States

Target Audience: Basic researchers with an interest the use of MRI to monitor obesity and therapeutic interventions.

Purpose: Obesity is associated with diabetes, cardiovascular disease and stroke. Recently, weight reduction surgeries, like Vertical Sleeve Gastrectomy (VSG), have been shown to reduce adverse clinical outcomes more than simple calorie restriction¹. The mechanism of this increased benefit with VSG is unknown, but may be due to incretin or bile acid signaling. While body weight and/or weight loss are important metrics of therapeutic effect, monitoring changes in the fat content within the abdomen or the liver may provide better correlation with the underlying disease processes. In a mouse model of obesity, we used fat-suppressed MRI and localized MR spectroscopy to quantify abdominal and liver fat following VSG.

Methods: Mice were fed a high fat diet (60% of calories from fat) for 6 weeks, and underwent no intervention (Naïve, n = 3), VSG (n = 6), or sham surgery with food restriction matching the VSG group (Sham/Pair Fed, n = 6). Two weeks later, mice were weighed and imaged at 7T. Axial T1 weighted MRI of the abdomen with and without fat suppression was used to quantify body fat content. The brightest pixels in the non-fat suppressed images were identified as fat pixels. These pixels were masked out of the fat suppressed images, and the remaining bright pixels were identified as water pixels. The number of fat pixels and water pixels were used to calculate the abdominal fat content as a percentage of the total abdominal volume. Respiratory gated proton MR spectra were collected from a 3 by 3 by 3 mm voxel within the liver. The ratio of the fat and water peaks in the spectrum was used to calculate the liver fat content in percent. The animals were sacrificed and liver triglyceride content was quantified by spectrophotometry with an enzymatic kit.

Results: The VSG and Sham/Pair Fed animals lost a significant amount of weight, reaching body weights of 27 and 28 g, respectively. In comparison, the Naïve mice weighed 33 g. Abdominal MRI showed a significant ($p < 0.05$) reduction in body fat in the VSG group, $10.4 \pm 2.1\%$, compared to the Sham/Pair Fed ($21.7 \pm 3.9\%$) and the Naïve ($22.1 \pm 4.1\%$) mice (**FIGURE 1**). Localized MR spectroscopy showed that the VSG mice had significantly lower liver fat ($1.3 \pm 0.4\%$, $p < 0.05$) than either the Sham/Pair Fed ($2.8 \pm 0.4\%$) or Naïve ($4.7 \pm 0.6\%$) animals. Likewise, ex vivo analysis of liver tissue showed decreased hepatic triglycerides in the VSG group (190 ± 35 mg/dl, $p < 0.05$) compared to sham/pair fed (401 ± 83 mg/dl) and naïve (693 ± 137 mg/dl). The agreement between the results from MR spectroscopy and ex vivo analysis of liver triglycerides yielded a correlation coefficient (R^2) of 0.9999 (**FIGURE 2**).

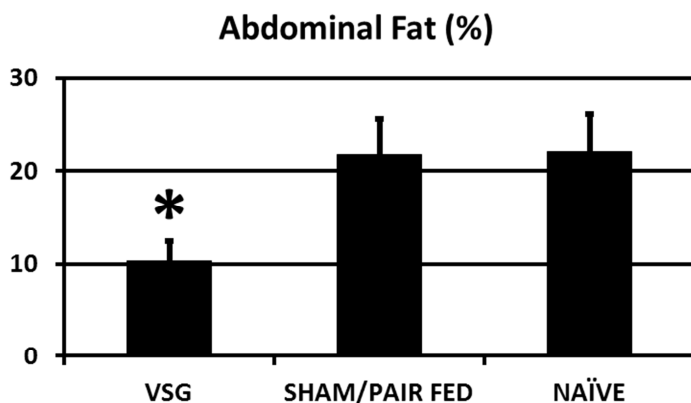


FIGURE 1: Abdominal MRI revealed decreased body fat in VSG mice compared to Sham/Pair Fed animals despite similar body weights and post surgery weight losses (* $p < 0.05$).

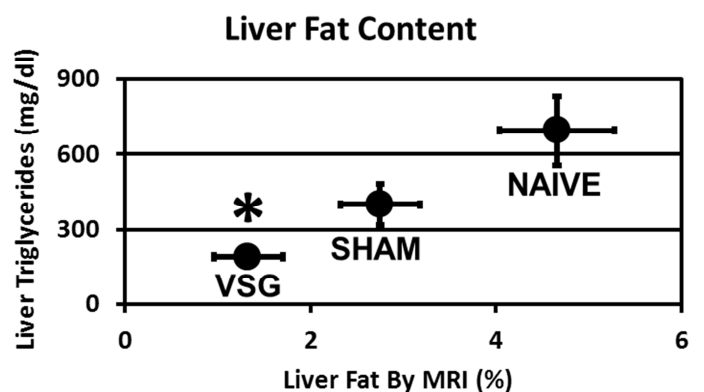


FIGURE 2: Correlation between liver fat content by MR spectroscopy and ex vivo tissue analysis. Both methods showed reduced liver fat in VSG mice compared to controls (* $p < 0.05$) with $R^2 = 0.9999$.

Discussion: Despite similarities in both body weight and weight loss, MRI of abdominal and liver fat content revealed higher fat in the Sham/Pair Fed animals compared to the VSG group. While simple measurements of body weight suggested that VSG and Sham/Pair Fed groups responded equally to each intervention, measurements of the fat content revealed that the Sham/Pair Fed animals were more similar to the Naïve group. Measurement of liver fat with localized MR spectroscopy agreed with ex vivo analysis of liver triglycerides, suggesting that MR spectroscopy could be used to noninvasively monitor liver response to weight loss interventions.

Conclusion: MRI and liver spectroscopy are attractive methods for monitoring abdominal and liver fat content following weight loss treatment, due to the noninvasive nature and ease of clinical translation. While the two treatment methods in this study, VSG surgery and sham surgery followed by calorie restriction, appeared to have similar effects on body weight, MR imaging and spectroscopy revealed significant differences in abdominal fat and liver fat between these groups.

References:

1. Kohli R, Stefater MA, Inge TH. Molecular insights from bariatric surgery. *Rev Endocr Metab Disord.* 12:211-217, 2011.