

# Supplemental Oxygenation and Hyper Ventilation for Accelerated 3D Late Gadolinium Enhancement Imaging of Left Ventricle Within a Single Breath Hold

Sébastien Roujol<sup>1</sup>, Tamer A Basha<sup>1</sup>, Mehmet Akçakaya<sup>1</sup>, Murilo Foppa<sup>1</sup>, Kraig V Kissinger<sup>1</sup>, Beth Goddu<sup>1</sup>, Sophie Berg<sup>1</sup>, Warren J Manning<sup>1,2</sup>, and Reza Nezafat<sup>1</sup>  
<sup>1</sup>Medecine, BIDMC / Harvard Medical School, Boston, MA, United States, <sup>2</sup>Radiology, BIDMC / Harvard Medical School, Boston, MA, United States

## Purpose/Introduction

2D Late gadolinium enhancement (LGE) MRI [1, 2] is commonly used for assessment of scar in the left ventricle [3]. 3D LGE is an alternative approach where the entire LV is imaged in a single scan, allowing higher spatial resolution and better coverage. However, 3D scans are usually long and require free-breathing acquisitions. For free-breathing LGE, respiratory navigator positioned on the right hemi diaphragm is used for gating and tracking of the motion. However navigator will increase the scan time by 2-3 times. A prolonged scan time in 3D LGE results in susceptibility to heart rate variation that manifest as signal variation and changes in the optimal inversion time due to contrast washout which manifest as incomplete myocardial signal nulling and artifacts. In this study, we sought to investigate the feasibility of an accelerated 3D LGE acquisition within one single prolonged breath hold using pre-oxygenation and hyperventilation. Initially, the impact of pre-oxygenation and hyperventilation on breath-hold duration, diaphragmatic drift and heart rate were studied. Subsequently, we used this approach to acquire 3D LGE images in a single long breath-hold using pre-oxygenation and hyperventilation.

## Materials and Methods

10 volunteers (28±15 years, 2 male) were recruited for this study and were imaged using a 1.5 T Phillips Achieva scanner (Philips Healthcare, Best, The Netherlands).

Breath hold characteristics (duration, motion drift, heart rate variation) were first evaluated with and without pre-oxygenation and hyper ventilation of the subjects. A 2D slice (imaging frame rate=10Hz, scan duration=3 minutes) was acquired in coronal orientation with a pencil-beam navigator positioned on the right hemi diaphragm to measure the potential motion drift of the diaphragm during each breath hold. Heart rate variation was measured during each breath hold by analysing the ECG information recorded with the scanner software. For each acquisition the subject was instructed to hold his/her breath for the longest time in the end-expiration. Each subject performed three breath holds (3 minutes between each breath hold). The first (BH#1) and last (BH#3) breath hold were performed without supplemental oxygen nor hyper ventilation while the second breath hold (BH#2) was performed with pre oxygenation of the subject (3min, 4L/min) and hyper ventilation (three fast maximum capacity deep breath).

### 3D LGE acquisitions:

Two 3D LGE sequences (TR/TE/α=5.2/2.6ms/25°, FOV=320×320×100 mm<sup>3</sup> resolution 1.6×1.6×5.0mm<sup>3</sup>) were acquired in a random order for each subject: a) a 4-fold accelerated navigator gated LGE scan (gating window=7mm), and b) a 4-fold accelerated breath hold (BH) LGE scan with pre-oxygenation (3min, 4L/min) and hyper ventilation (three fast maximum capacity deep breath) of the subject. Both sequences were performed 10 to 20 minutes after injection of the contrast agent. Accelerated image acquisition was achieved using a prospective randomly undersampled k-space acquisition. The undersampling pattern was designed to fully acquire 21×9 center lines in k<sub>y</sub>-k<sub>z</sub> and to randomly undersample the outer k-space to reach an overall undersampling factor of 4. Note that a phase reordering technique was employed to minimize eddy current artifacts [4]. Image reconstruction was performed using an improved CS based reconstruction [5]. The reconstructed images were scored by a blinded reader for image quality based on a 4-point scale (1-poor; 2-moderate; 3 good; 4-excellent) and diagnostic value (yes/no).

## Results

Figure 1 shows the navigator signal recorded during breath holds performed with and without pre-oxygenation and hyperventilation. Longest breath holds were achieved using pre-oxygenation and hyperventilation as confirmed over all subjects (see Table 1) where the duration of BH#2 was found significantly longer than in BH#1 (p<0.01) and BH#3 (p<0.01). No significant difference was found in term of diaphragmatic motion drift and heart rate variation between the breath holds. Figure 2 shows reconstructed 3D LGE images acquired with a navigator gated approach (left) and within a prolonged breath hold (right) in three subjects. All subjects could successfully hold their breath for the entire duration of the BH-LGE acquisition. All LGE images were identified as diagnostic with no significant difference on image quality score: 3.3±0.67 for BH-LGE and 3.2±0.63 for navigator-gated LGE (p=0.67). Over all volunteers, BH-LGE significantly reduced the overall scan time from 81±12s (navigator gated LGE) to 37±6s (p<0.001).

## Conclusions

3D accelerated LGE imaging can be performed within one single prolonged breath hold using pre-oxygenation and hyper ventilation and allows a significant reduction of the acquisition time without compromising image quality.

## Acknowledgements

The authors acknowledge grant support from NIH R01EB008743-01A2.

## References

[1] Kim et al., N Engl J Med, 2000 [2] Simonetti et al., Radiology, 2001 [3] Schmidt et al., Circulation, 2007 [4] Basha et al., ISMRM, 2011 [5] Akçakaya et al., Radiology, 2012

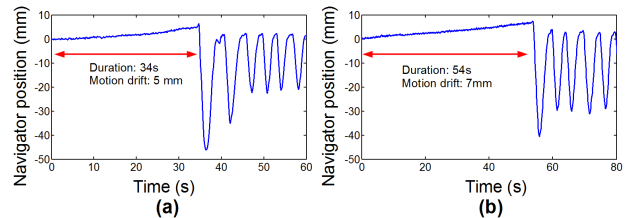


Figure 1. Navigator signal recorded during breath hold performed without (a) and with (b) pre oxygenation and hyper ventilation.

	BH duration	Diaphragmatic motion drift	Maximum hear rate variation
BH#1	40±14s	5.9±4.0mm	14±8 bpm
BH#2	58±21s	7.0±4.6mm	13±5 bpm
BH#3	41±16s	6.9±4.2mm	14±5 bpm
BH#1 vs. BH#2	p=0.005	p=0.42	p=0.82
BH#2 vs. BH#3	p=0.007	P=0.30	P=0.83
BH#1 vs. BH#3	p=0.79	p=0.90	p=0.40

Table 1. Breath hold characteristics obtained with (BH#2) and without (BH#1, BH#3) pre-oxygenation and hyper ventilation.

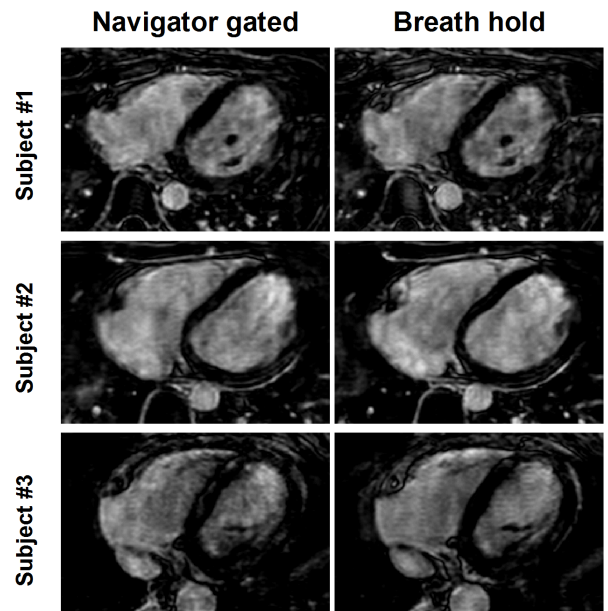


Figure 2. 3D axial LGE images (undersampling rate=4) obtained in 3 subjects using a navigator gated acquisition (left) and within a single breath hold (right). Similar image quality was obtained using both approaches.