

Physiology-based MRI Assessment of CSF Flow at the Foramen Magnum with a Valsalva Maneuver

Samuel Patz^{1,2}, Yansong Zhao³, Neel Madan⁴, Mark E. Wagshul⁵, James P. Butler^{2,6}, and Rafeeqe A. Bhadelia^{2,7}

¹Radiology, Brigham & Women's Hospital, Boston, MA, United States, ²Harvard Medical School, Boston, MA, United States, ³Philips Healthcare, Columbus, OH, United States, ⁴Radiology, Tufts Medical Center, Boston, MA, United States, ⁵Gruss Magnetic Resonance Research Center, Albert Einstein College of Medicine, Bronx, New York, United States, ⁶Sleep Medicine, Brigham & Women's Hospital, Boston, MA, United States, ⁷Radiology, Beth Israel Deaconess Medical Center, Boston, MA, United States

Introduction

Invasive pressure studies have shown physiological challenges such as the Valsalva maneuver or coughing produce transient changes in intracranial and intraspinal pressures (1). While such transients are rarely of significance in normal subjects, for patients with foramen magnum obstruction, e.g. Chiari I malformation, such transients may be responsible for producing headache and syringomyelia (2-7). In the past, attempts were made to use CSF pressure measurements with physiological challenges as a clinical test (5,7). However, these methods have not gained widespread acceptance because they are invasive. Here we evaluate two MRI methods in healthy subjects to measure CSF flow before, during, and after a controlled Valsalva maneuver.

Method

An undersampled cardiac-gated fast 2D cine phase-contrast (cine-PC) sequence with ≤ 15 s acquisition time, similar to that reported by Wentland et al. (8), was used to assess CSF flow in 8 healthy subjects at the foramen magnum. CSF mean displacement volume (\bar{V}_{CSF}) during the cardiac cycle and CSF flow waveform peak to peak amplitude (A_{pp}) were determined. A real-time 1D pencil-beam imaging (PBI) method with temporal resolution ≤ 56 milliseconds was used to scan two subjects for 90 seconds during which resting, Valsalva, and post-Valsalva CSF flow, respiration, and heart rate were continuously recorded. Results were evaluated by comparison with invasive craniospinal differential pressure measurements from the literature (1). All scans were performed on a Philips 3T scanner (Philips Healthcare, Best, The Netherlands) at Tufts Medical Center.

Results

Both methods showed (1) a decrease from baseline in \bar{V}_{CSF} and A_{pp} during Valsalva and (2) an increase in \bar{V}_{CSF} and A_{pp} immediately after Valsalva, compared to values measured both at rest and during Valsalva. While fast cine-PC produced a single CSF flow waveform that is a k-space weighted average over many cardiac cycles, PBI quantified waveforms for each heart beat and was able to capture many dynamic features of CSF flow, including transients synchronized with the Valsalva maneuver. An example of PBI results is shown in Figure 1. From left to right, resting, Valsalva, and post-Valsalva periods are seen. Just before Valsalva onset, there is a large respiratory bellows movement due to inspiratory effort (arrow). During Valsalva, a decrease in the CSF flow waveform peak to peak amplitude A_{pp} (waveform envelope) and displacement volume \bar{V}_{CSF} are seen with simultaneous increase in heart rate and suspension of respiration. The end of Valsalva is seen as a resumption of normal respiration (arrowhead). In the immediate post-Valsalva period, heart rate decreases and both \bar{V}_{CSF} and A_{pp} are higher than resting values, consistent with a post-Valsalva rebound.

Discussion

Invasive pressure measurements of Williams (1) show a gradual decrease in craniospinal pressure difference during the Valsalva followed by a sharp rebound in pressure fluctuation amplitude on its termination. This is mirrored in the flow behavior revealed by the PBI approach and is consistent with flow, especially in its transient behavior, being driven by corresponding fluctuations in pressure in the spinal column coincident with the heart beat. Importantly, we note that these transient flow changes associated with the onset and termination of the Valsalva maneuver are seen with PBI and not cine-PC. Unlike fast cine-PC, PBI can simultaneously assess changes both above and below the level of the foramen magnum, along the length of the excitation cylinder, and it does not require cardiac gating. This eliminates the problem of gating interruption due to sudden changes in heart rate during the Valsalva maneuver.

Conclusion

We believe the real-time capability of PBI makes it an ideal candidate to detect and quantify transient CSF flows in response to a Valsalva maneuver, and which are altered in patients with foramen magnum obstruction.

Acknowledgements

This work was supported by the Conquer Chiari Foundation.

References

1. Williams B. *Acta Neurochir (Wien)* 1981;58:167-185.
- 2-7. Bhadelia RA, et al., *Am J NeuroRadiology*, 2011 Apr;32(4):739-42; 3. Heiss JD, et al. *J Neurosurg* 1999;91:553-562; 4. Sansur CA, et al. *J Neurosurg* 2003;98:453-458; 5. Tachibana S, et al. *J Neurosurg* 1992;76:67-71; 6. Williams B. *J R Soc Med* 1980;73:798-806; 7. Williams B. *Arch Neurol* 1980;37:226-230.
8. Wentland AL et al. *Proc Intl Soc Mag Reson Med*; 2006;152.

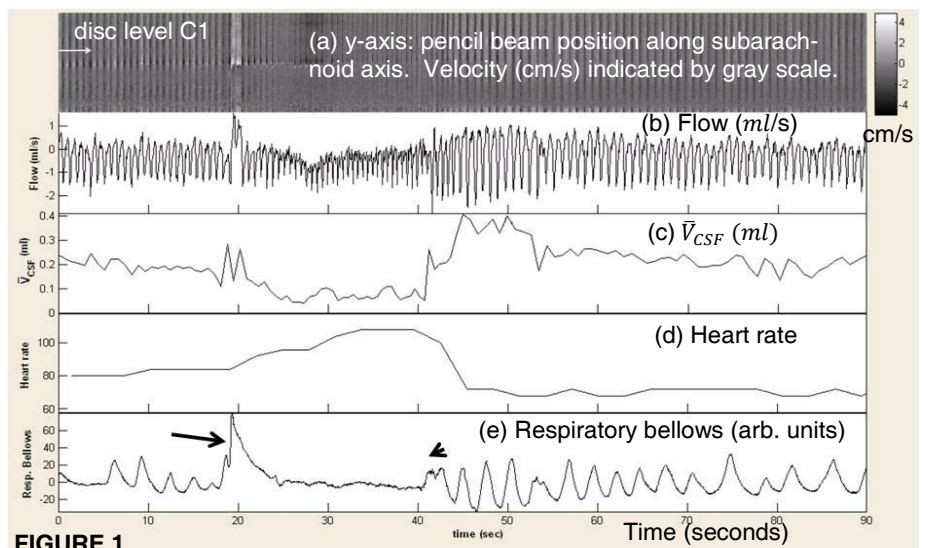


FIGURE 1.