

# MR imaging of Meniere's disease by intratympanic (IT) and intravenous (IV) injection of Gd-DTPA: Double contrast injection and a novel imaging strategy, HYDROPS2 for IT+IV

Shinji Naganawa<sup>1</sup>, Masahiro Yamazaki<sup>1</sup>, Hisashi Kawai<sup>1</sup>, Kiminori Bokura<sup>1</sup>, Michihiko Sone<sup>2</sup>, and Tsutomu Nakashima<sup>2</sup>

<sup>1</sup>Department of Radiology, Nagoya University Graduate School of Medicine, Nagoya, Aichi, Japan, <sup>2</sup>Department of Otorhinolaryngology, Nagoya University Graduate School of Medicine, Nagoya, Aichi, Japan

**Target audience;** Radiologists and physicists, especially who are responsible to set up clinical MR protocols

**Purpose;** Visualization of endolymphatic hydrops (EH) in Ménière's disease (MD) is currently performed by 3D-real IR imaging after intratympanic Gd-DTPA injection (IT) [1, 2] or heavily T2-weighted (hT2w)-3D-FLAIR after single dose intravenous Gd-DTPA injection (IV)[3]. IT method can usually provide higher contrast than IV method and can also predict the intralabyrinthine distribution of intratympanically injected gentamicin. However, IT method needs off-label use of Gd-DTPA, invasive puncture of tympanic membrane. Therefore, unilateral IT injection is usually performed. IV method can evaluate bilateral ears simultaneously, but pulse sequences used for IV method need to be sensitive enough to detect very low concentration Gd-DTPA. Imaging parameters used for IT and IV method are different. We have begun to perform simultaneous IT+IV double contrast method to simulate drug distribution in one ear and to evaluate EH in the other ear. In other words, one ear gets only IV contrast and the other gets IT+IV contrast. The purpose of this study was to propose the novel imaging method that is suitable to evaluate both ears simultaneously.

**Methods;** Ten patients with clinical suspect of Ménière's disease (6 men, 4 women, age range: 35-68 years old) were scanned at 3T. All patients received IT of 8-folds diluted Gd-DTPA in one ear 24 hours prior to MR scan and single dose IV of Gd-DTPA 4 hours prior to MR scan. Pulse sequence parameters are as follows; MR cisternography (MRC, 4400/544, 3min scan time) for the anatomical reference of total lymph fluid, hT2w-3D-FLAIR (positive perilymph image, PPI, 9000/544/2250,14min) and 3D-inversion recovery with real reconstruction (3D-real IR, 6000/182/1650, 15min) were obtained. The subtraction of MRC from PPI has been reported to enable the 3D-real IR like image presentation after IV[4]. This procession was named as

**"HYDROPS2" image: HYbrid of Reversed image Of MR cisternography and positive Perilymph Signal by heavily T2-weighted 3D-FLAIR image.**

HYDROPS2 images are generated by the subtraction of MRC multiplied by 0.05 from PPI on scanner console. Presence of contrast enhancement of perilymph in cochlea, vestibule and semicircular canals (SCCs) and degree of EH was graded by two neuroradiologists with consensus. Medical ethics committee approved this study and all patients gave written informed consent.

**Results;** In all ears, HYDROPS2 images enabled the assessment of EH, however 3D-real IR images allowed the assessment of EH only in IT+IV side. In all only-IV side ears, 3D-real IR failed to detect the enhancement of perilymph. HYDROPS2 detected the enhancement of perilymph in all cochlea, vestibule and 58 semicircular canals out of 60. Grades of EH in IT+IV side agreed between HYDROPS2 and 3D-real IR(Fig.1-2).

**Discussion and Conclusion;** HYDROPS2 can replace 3D-real IR in the cases of IT+IV protocol. HYDROPS2 image can evaluate only-IV side and IT+IV side simultaneously. This contributes to the dramatical shortening of the examination time and might reduce the possibility of failure due to motion and weak enhancement.

## References

- [1] Nakashima T, et al. Laryngoscope 117(3): 415-420, 2007
- [2] Naganawa S, et al. Eur Radiol 18(5):920-924, 2008
- [3] Naganawa S, et al. Magn Reson Med Sci 11:145-50, 2012
- [4] Naganawa S, et al. Magn Reson Med Sci, in press

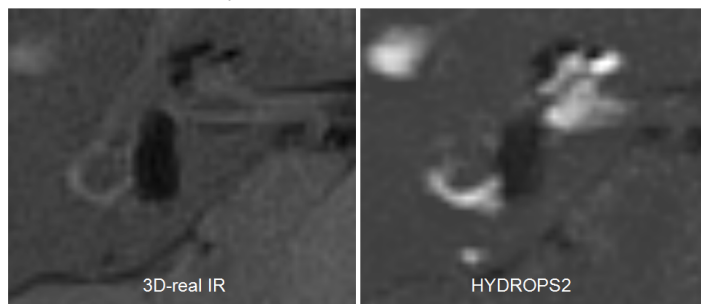


Fig. 1 A 44-years old man. IT+IV side. Note the enhancement of perilymph is far weaker on 3D-real IR than on HYDROPS2. Significant EH can be seen in cochlea and vestibule on both images.

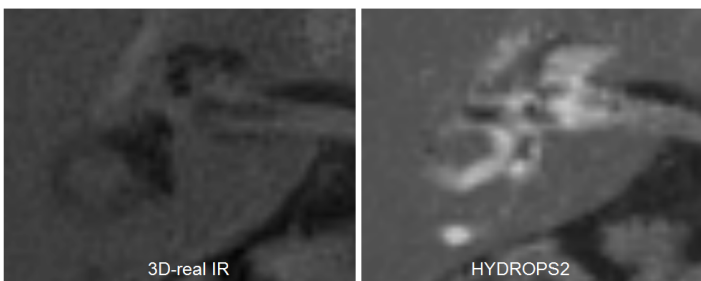


Fig. 2 A 47 years old man. IV-only side. Note the enhancement of perilymph is absent on 3D-real IR. Significant EH can be appreciated in cochlea and vestibule only on HYDROPS2 image.