

# Textural analysis of echo-planar diffusion-weighted imaging improves preoperative characterisation of suspected thyroid tumours

Anna M Brown<sup>1,2</sup>, Sidhartha Nagala<sup>3</sup>, Daniel Scoffings<sup>4</sup>, Mary McLean<sup>2</sup>, Andrew Priest<sup>4</sup>, Piyush Jani<sup>3</sup>, and John Griffiths<sup>2</sup>

<sup>1</sup>School of Medicine, Duke University, Durham, NC, United States, <sup>2</sup>Department of Oncology, University of Cambridge, Cambridge, Cambridgeshire, United Kingdom,

<sup>3</sup>Department of Otolaryngology, Addenbrooke's Hospital, University of Cambridge, Cambridge, Cambridgeshire, United Kingdom, <sup>4</sup>Department of Radiology, Addenbrooke's Hospital, University of Cambridge, Cambridge, Cambridgeshire, United Kingdom

**TARGET AUDIENCE:** Radiologists and Clinical Researchers studying Thyroid Cancer; MR Researchers studying Texture Analysis

**PURPOSE:** To assess whether textural analysis (TA) could improve accuracy, sensitivity, and specificity of discrimination between malignant and benign thyroid nodules using diffusion-weighted MRI (DW-MRI).

**METHODS:** 3 Tesla DW-MRI images were obtained with a diffusion-weighted dual-spin-echo echo-planar imaging (DW-EPI) sequence (TE = 81 ms; TR = 2200 ms; field of view (FOV) 22 cm; matrix 128x128; 16 averages; slice thickness 5 mm; spacing 1 mm; b-values of 0 and 500 s/mm<sup>2</sup>). A consultant neuro-radiologist blinded to the clinical data drew regions of interest (ROIs) around the lesions. TA and linear discriminant analysis (LDA) on 26 patients using MaZda and b11 (Technical University of Łódź, Wólczajska, Poland) gave >300 texture parameters; feature reduction selected 30 that best distinguished the benign and malignant ROIs. The resultant most discriminant factor 1 (MDF1) values gave sensitivity and specificity values and ROC curves (GraphPad Prism, San Diego, California, USA). The data set was divided into 20 patients in the training set and 6 patients in the test set, with malignant and benign thyroid nodules represented in both sets.

**RESULTS:** TA of the training set correctly classified 83/87 slices, giving a sensitivity of 87% and specificity of 100% with a cut-off MDF1 value of -0.0331 (Figure 1). Selecting the highest scoring slice per patient on the basis of MDF1 achieved 100% specificity and 92% sensitivity, with 18/20 nodules correctly classified. When these parameters were used on the test set, 11/14 slices and 5/6 nodules were correctly classified (Figure 2).

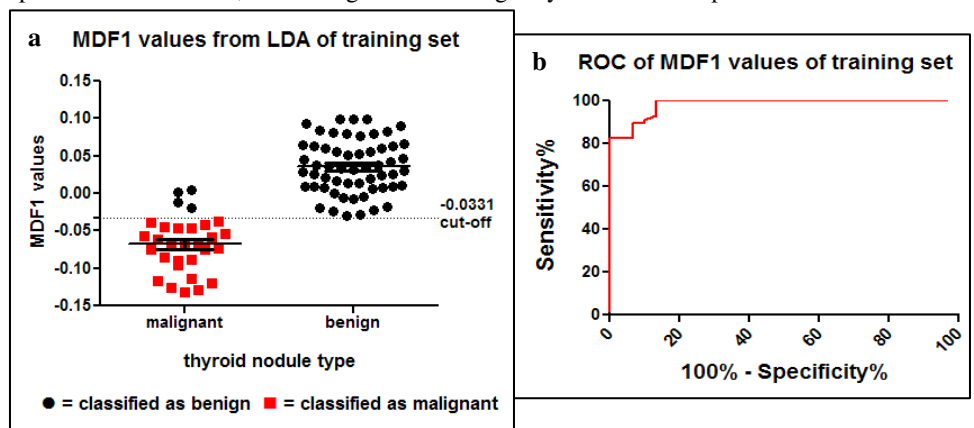
**DISCUSSION:** Our results comparing mean ADCs between the benign and malignant groups are consistent with recent reports, with higher ADCs in benign thyroid nodules compared to malignant nodules.<sup>1,2</sup> This supports the hypothesis that increased cellularity and a reduction in the extracellular extravascular space in malignant nodules results in restricted diffusion.<sup>3</sup> Yet the mean ADC value may not be best for discriminating between benign and malignant nodules, since mean values fail to account for complex tumor pathology. Using TA, we discovered the most discriminatory texture parameters and generated a model using LDA to differentiate between benign and malignant nodules. The TA results were very promising, achieving 87% sensitivity and 100% specificity values with a cut-off value of -0.0331 for the MDF1 values resulting from the LDA output. The sensitivity increased to 92% by isolating the highest scoring slices per nodule on the basis of MDF1. The MDF1 cut-off value held up reasonably well with test set data, resulting in 11/14 slices and 5/6 nodules correctly classified. The results of our study indicate great potential for TA to be used on DW-EPI images of thyroid nodules. If malignant nodules can be reliably identified using this method, patients may only need one definitive procedure and could be spared unnecessary operations associated with the diagnostic lobectomy.

**CONCLUSION:** TA classifies DW-EPI images of thyroid nodules with high sensitivity and specificity. A large prospective study is now needed to fully prove this model.

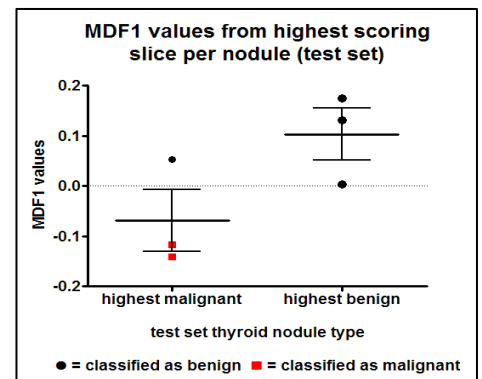
**ACKNOWLEDGEMENTS:** We'd like to thank Cancer Research UK, the Addenbrookes Charitable Trust, the University of Cambridge, the Cambridge Experimental Cancer Medicine Centre, and the NIHR Cambridge Biomedical Research Centre.

## REFERENCES

1. Bozgeyik Z., Coskun S., Dagli A.F., et al. Diffusion-weighted MR imaging of thyroid nodules. *Neuroradiology*. 2009;51:193-198
2. Dilli A., Ayaz U.Y., Cakir E., et al. The efficacy of apparent diffusion coefficient value calculation in differentiation between malignant and benign thyroid nodules. *Clin Imaging*. 2012;36:316-322
3. Colagrande S., Carbone S.F., Carusi L.M., et al. *Radiol Med*. Magnetic resonance diffusion-weighted imaging: extraneurological applications. 2006;111:392-419



**Figure 1:** Linear discriminant analysis (LDA) of the training set for most discriminant factor 1 (MDF1). (a) MDF1 values for benign and malignant slices. 83/87 slices correctly classified. (b) ROC curve for the MDF1 values as a diagnostic tool, with a cut-off value of -0.0331. P < 0.0001 and area under the curve = 0.98



**Figure 2:** LDA classification of test set for highest scoring MDF1 values with cut-off: -0.0331. 5/6 nodules classified correctly.