

Normalized quantitative Magnetic Resonance Imaging on Multiple Sclerosis

JBM Warntjes¹, M Engström^{1,2}, A Tisell^{1,3}, I Blystad^{1,2}, A-M Landtblom^{1,4}, and P Lundberg^{1,3}

¹Center for Medical Imaging Science and Visualization, Linköping, Sweden, ²Department of Medical and Health Sciences, Radiology, Linköping, Sweden, ³Department of Medical and Health Sciences, radiation Physics, Linköping, Sweden, ⁴Department of Clinical and Experimental Medicine, Neurology, Linköping, Sweden

Introduction

In Multiple Sclerosis focal white matter lesions are regarded as a hallmark pathological finding. Generally the diffuse white matter changes are not taken into account. A method was developed to quantify these diffuse changes for a group of MS patients. The method consists of quantitative MRI to determine the longitudinal relaxation rate (R_1), the transverse relaxation rate (R_2) and the proton density (PD), in combination with a method to normalize individual brains into a standard template. The averaged, normalized R_1 , R_2 and PD maps will highlight common traits of the whole MS group whereas individual, focal lesions are suppressed.

Methods

Quantitative MRI was used to simultaneously obtain R_1 , R_2 and PD using previously reported sequence¹. The sequence consisted of 4 saturation delays with 5 echoes for each acquisition resulting in $4 \times 5 = 20$ images per slice. The resolution was $1 \times 1 \text{ mm}^2$, 30 axial slices of 4 mm thickness were collected in a scan time of 8:21 minutes. The scanner was an Achieva 1.5 T (Philips Healthcare, Best, The Netherlands).

R_1 , R_2 and PD were measured in the brains of 20 patients diagnosed with Clinically Definite Multiple Sclerosis (mean age 48 ± 12 years, mean EDSS 3.6 ± 2.2 , 6 male, 14 female) and 20 age- and gender matched healthy subjects. The maps were re-gridded to $2 \times 2 \times 2 \text{ mm}$ to obtain an isotropic dataset. A T2-weighted image stack was synthesized and used in a 12-parameter affine regularization to a standard stereotactic space in Montreal Neurological Institute (MNI) coordinates using SPM8 (Wellcome Department of Imaging Neuroscience, London, UK)². The same transformation matrix was applied to the R_1 , R_2 and PD maps. Mean values and t-statistics were calculated to determine group differences.

Results

In Fig. 1 a slice of normalized, mean R_1 , R_2 and PD values is shown for the MS patient group. The standard deviation of these maps was high at the edges of the brain and the ventricles, moderate in the cortical grey matter and low in white matter and the deep grey matter structures. In Fig. 2 the t-statistics are shown between MS patients and healthy subjects, where significantly lower R_1 and R_2 and higher PD values were observed throughout the periventricular white matter and centrum semi-ovale.

Discussion and conclusions

The proposed method quantifies diffuse hyper-intensities that a group of MS patients have in common. The use of quantitative MRI makes it MR scanner independent since it only reflects tissue characteristics. Brain normalization results in a fully automatic method where individual traits such as shape and size are removed. Individual, focal MS lesions are suppressed by averaging.

A limitation of the method is the accuracy of the brain normalization method on patients who show many lesions, substantial brain atrophy or large ventricles, which can make it difficult to discern tissue loss from tissue changes. Furthermore the image resolution is limited. More clinical validation is required to determine the sensitivity and specificity of the method. Brain normalization of qMRI maps is a promising method to investigate diffuse changes of the brain, common to a complete group.

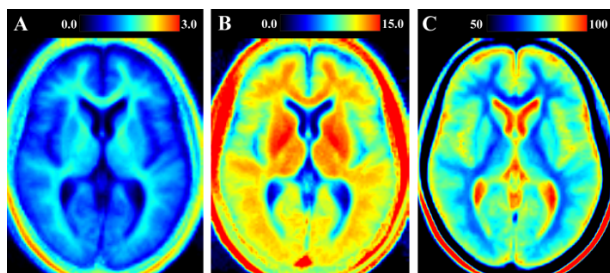
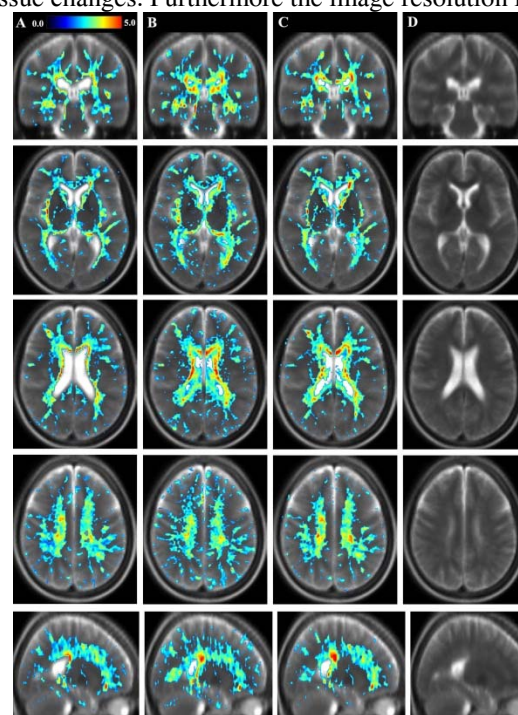


Fig. 1. Example of the normalized qMRI maps pooled across a group of MS patients with **A:** R_1 relaxation rate on a scale $0-3 \text{ s}^{-1}$, **B:** R_2 relaxation rate on a scale $0-15 \text{ s}^{-1}$ and **C:** proton density on a scale $50-100\%$, where 100% corresponds to water at 37°C .

Fig. 2. Results from two-sample t-tests comparing MS patients and healthy controls shown as color overlay t-values > 2 for **A:** R_1 , **B:** R_2 , **C:** PD. **D:** Synthetic T2-weighted images of the MS patient group were calculated using the R_1 , R_2 and PD maps and used as background images. One coronal, three axial and one sagittal slice are shown.



[1] Warntjes JBM, et al. Rapid Magnetic Resonance Quantification on the Brain. *Magn Reson Med* 2008;60:320-329.

[2] Friston KJ, et al. Spatial registration and normalization of images. *Hum Brain Mapp* 1995;3:165-189