

Automatic Detection and Quantification of Progressive Brain Atrophy in Dementia

Audrunas Gruslys¹, Julio Acosta-Cabronero², Peter J Nestor³, Guy B Williams⁴, and Richard E Ansorge¹

¹Department of Physics, University of Cambridge, Cambridge, England, United Kingdom, ²Department of Clinical Neurosciences, University of Cambridge, Cambridge, England, United Kingdom, ³German Center for Neurodegenerative Diseases (DZNE), Magdeburg, Germany, ⁴Wolfson Brain Imaging Centre, University of Cambridge, Cambridge, England, United Kingdom

Target audience: Neuroscientists doing longitudinal disease studies

Purpose: Presently, there is considerable interest in trying to expedite therapeutic development through the use of MRI biomarkers. In this context, our goal was to develop a fully-automated algorithm capable of detecting and quantifying longitudinal volume changes in single dementia patients using T1-weighted MRI brain images acquired at different time-points.

Methods: Whole-brain anatomical scans were acquired in a Siemens Trio 3T system using a standard MPRAGE sequence (voxel resolution: 1.25 mm³ isotropic). Eighteen participants were recruited for this experiment: 5 elderly controls, with scanning sessions taking place at baseline, 6 and 12 months; 6 clinical patients diagnosed with Alzheimer's disease (AD), who were scanned at the same 3 time-points; and 7 semantic dementia (SD) patients, who only had 2 scans ranging from 17 to 38 months apart. 'Rate-of-shrinkage' maps were computed for each individual by registering each image pair (iteratively for 3 time-points) using our in-house developed GPU-enabled Ezys¹ non-linear image registration program set to maximise normalised mutual information². Two-hundred and fifty four non-linear image registrations were performed needing on average 26 seconds per registration, which led to a total processing time of 110 minutes and averaged at around 6 minutes per subject. For each subject we obtained Jacobian fields that reflected local brain-tissue changes between time-points. To facilitate comparison across subjects, rates of change were normalised both spatially and quantitatively by warping Jacobian maps to a fixed structural template and regressing each logarithmic Jacobian map (in common space) against longitudinal time-spans. Ezys includes a novel regularization algorithm for non-linear registration which attempts to preserve boundaries between anatomical regions. The computational speed-up from using a GPU greatly facilitated the development of workflows with multiple registration steps.

Results & Discussion: Fig. 1 illustrates the measured rates of change for 6 individuals: 2 controls, 2 ADs and 2 SDs. Clearly recognizable patterns of progressive atrophy were observed in dementia patients: in AD, parietal and temporal lobe areas bilaterally featured prominently; whereas in SD, more focal, progressive temporal damage was observed. It was noted that SD subjects who presented with highly-atrophic left temporal lobes appeared to progress more prominently on the right side (see column 6 in Fig. 1); though as expected, milder SD subjects, who had relatively more preserved hippocampae, showed preferential decline in left temporal areas. Elderly controls, in contrast, showed less widespread and overall less intense rates of change. Detected changes were consistent with our prior knowledge of disease progression. Each condition could be visually identified by looking to detected atrophy maps only (Fig. 1).

Conclusions: The proposed method was successful in detecting condition-specific local volume changes, which highlights its potential for tracking disease progression in single subjects.

References:

1. Gruslys A, Sawiak S, Ansorge R. 3000 Non-Rigid Medical Image Registrations Overnight on a Single PC. 2011 IEEE Nuclear Science Symposium and Medical Imaging Conference:3073-3080.
2. Wells WM, 3rd, Viola P, Atsumi H, Nakajima S, Kikinis R. Multi-modal volume registration by maximization of mutual information. Medical image analysis. 1996; 1(1):35-51.

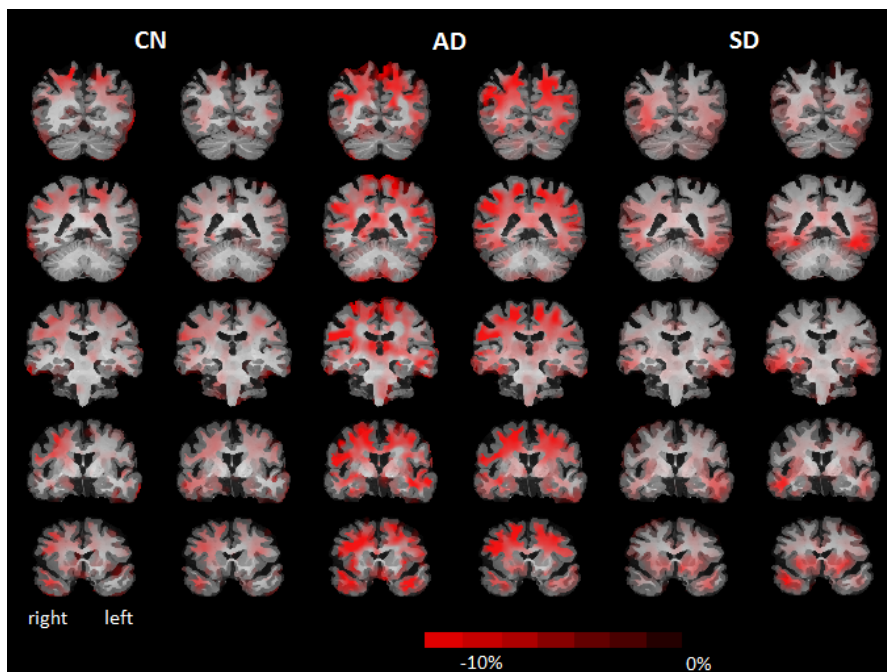


Fig. 1. Rates of shrinkage for 2 controls, 2 Alzheimer's disease and 2 semantic dementia patients overlaid onto a target template (an elderly-control subject). Progressively atrophic areas are highlighted in red. Five slices shown for each subject.