

Blood-Brain Barrier pathology in Dementia: Dual Time Resolution Dynamic Contrast Enhanced-MRI assessment

Harm J van de Haar¹, Saartje Burgmans¹, Thijs van Osch², Jacobus Jansen³, Frank van Bussel¹, Cecile Jeukens³, Mark van Buchem², Paul Hofman³, Frans Verhey¹, and Walter Backes³

¹Maastricht University, Maastricht, Limburg, Netherlands, ²Leiden University Medical Center, Leiden, Zuid-Holland, Netherlands, ³Maastricht University Medical Center, Maastricht, Limburg, Netherlands

Target audience. Neuroscientists, neuroradiologists, physicists

Purpose. A potential underlying mechanism for dementia through Alzheimer's Disease (AD) could be that microscopic vascular abnormalities cause leakage of the blood brain barrier prior to neuronal damage. A dual-temporal resolution Dynamic Contrast Enhanced (DCE)-MRI can be used to detect these microscopically small lesions. DCE-MRI has been widely used to study blood supply in (high-grade) tumors where the leakage may be relatively large. However, when studying normal brain tissue or white matter lesions, where the expected leakage, if any, is very small, DCE-MRI is a relatively new technique in the context of cerebrovascular disease¹. By using a fast DCE-MRI sequence during contrast agent injection, the arrival of the contrast agent in the microvascular blood space can be studied, while a subsequent slower, but higher spatial resolution scan allows for a more precise assessment of the possible leaking blood-brain barrier. The primary aim of this pilot study is to assess the feasibility of detecting differences in terms of pharmacokinetic parameters fractional blood volume (v_b) and leakage (K_i) in brains suffering from (preclinical) AD with a dual-temporal resolution DCE-MRI sequence, particularly focused on white matter abnormalities. Also, the minimally required scan duration was investigated.

Methods. Acquisition: The acquisition protocol consisted of two integrated DCE-MRI sequences (3 T Achieva TX). An ultra fast gradient echo (TR/TE 4.4/2.14 ms, 25.6x25.6x4.5 cm³ FOV, 256x256x10 voxels) was used during bolus injection until 1.5 minutes had passed, resulting in 37 volumes including 12 precontrast scans. Immediately afterwards a different fast gradient echo (TR/TE 5.6/2.5 ms, 25.6x25.6x10 cm³ FOV, 256x256x50 voxels) was used for 27.5 minutes resulting in 63 volumes including 3 precontrast scans. The two scans had overlapping coverage for the periventricular region. The contrast agent, gadobutrol, was injected intravenously (dose 0.1 mmol/kg, injection rate 3 ml/s) using a power injector. T2w-FLAIR scans were used to detect white matter abnormalities.

Subjects: 5 patients with Mild Cognitive Impairment (MCI) and 3 patients with AD (mean age 78.1 ± 6.3 years) were scanned on two identical MRI systems. Written informed consent was obtained from all subjects.

Analysis: On T2w-FLAIR scans, one region per patient containing normal appearing white matter (NAWM) and, if present, periventricular abnormal appearing white matter (AAWM) were identified. These regions were examined for the slow dynamic volumes. The relative signal change was converted to contrast agent concentration using a linear approximation method². A vascular input function (VIF) was extracted from a region of interest in the sagittal sinus for both scans. Using the graphical Patlak³ model, the transfer constant K_i and blood volume fraction v_b were calculated per ROI. The pharmacokinetic parameters were calculated as a function of scan duration. The standard error within and between subjects was calculated to determine the minimum scan time for stable pharmacokinetic parameters and group differences, respectively.

Results. Example concentration curves are depicted in figure 1. Figure 2 shows the calculated K_i and v_b as a function of scan duration. For the first 10 minutes the values of K_i are variable and the within subject errors of K_i and v_b are relatively large. v_b was significantly higher in the AAWM compared to NAWM, from a post-injection scanning time of 10 minutes and later (see fig. 2). K_i was slightly, but not significantly, higher for AAWM compared to NAWM. Calculations of K_i for NAWM provided small, but not significant, negative values due to the fact that NAWM enhances somewhat earlier than the venous VIF.

Discussion. Contrast enhancement in both NAWM and AAWM is highly due to the filling of blood space. Fractional blood volume differences were detected between AAWM and NAWM, in accordance with previous work⁴, and reflect vascular pathology. Contrast leakage is more difficult to detect and will require more subjects before a significant effect will become apparent.

Conclusion. Fractional blood volume in AAWM is significantly larger compared to NAWM, which suggests microvascular volume abnormalities rather than measurable hyperpermeability. At least 10 minutes of post-contrast scanning time is needed to observe these differences.

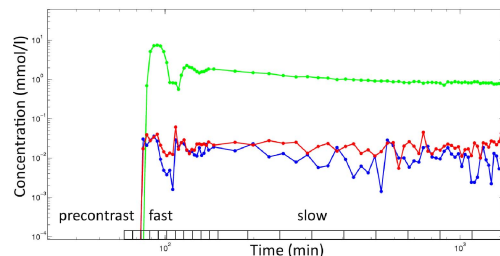


Figure 1: The concentration curves of fast and slow combined of one patient on a double logarithmic scale. Note the early multiple passes of the contrast agent in both the VIF (green) and the NAWM (blue) and AAWM (red), which is indicative for blood space.

References.

1. Taheri S et al. MRM 2011;65(4):1036–1042.
2. Schabel MC, Parker DL. Phys Med Biol. 2008;53(9):2345–73.
3. Patlak C et al. J Cerebr Blood F Met. 1983;3(1):1–7.
4. Wardlaw JM et al. Stroke. 2003;34(3):806–12.

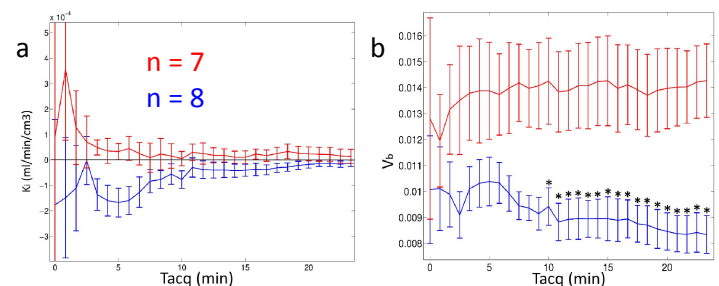


Figure 2: K_i (a) and v_b (b) as a function of scan time (Taqc) with the standard error between subjects for ROI's in NAWM (blue) and AAWM (red). * indicates significant difference (Student's t-test, $p < 0.05$).