

# Classification of hyperintense FLAIR lesion area in patients with glioblastoma following treatment with bevacizumab

Moran Artzi<sup>1,2</sup>, Orna Aizenstein<sup>1</sup>, Deborah T. Blumenthal<sup>3</sup>, Felix Bokstein<sup>3</sup>, Benjamin W. Corn<sup>2,4</sup>, and Dafna Ben Bashat<sup>1</sup>

<sup>1</sup>The Functional Brain Center, The Wohl Institute for Advanced Imaging, Tel Aviv Sourasky Medical Center, Tel Aviv, Israel, <sup>2</sup>Sackler Faculty of Medicine, Tel Aviv University, Tel Aviv, Israel, <sup>3</sup>Neuro-Oncology Service, Tel Aviv Sourasky Medical Center, Tel Aviv, Israel, <sup>4</sup>Institute of Radiotherapy, Tel Aviv Sourasky Medical Center, Tel Aviv, Israel

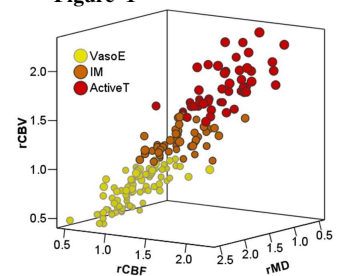
## Background / Aims:

Bevacizumab (BVZ), a humanized monoclonal antibody to vascular endothelial growth factor, has been shown reduction in MRI contrast enhancement and vasogenic edema in patients with Glioblastoma (GB)<sup>1-3</sup>. However, the substantial response seen on MRI does not appear to lead to a proportional improvement in survival time<sup>4</sup>. Several studies have demonstrated that following BVZ therapy, GB is more likely to progress as a non-enhancing tumor, associated with increased MRI T2W signal<sup>1-4</sup>. As a result the radiological criteria for the assessment of therapy response to BVZ were expanded to include T2 hyperintense areas<sup>1</sup>. However, non-enhancing tumors can be difficult to differentiate from other causes of FLAIR/T2. The aim of this work was to propose a method to differentiate between the vasogenic and tumoral components of T2 hyperintensity in patients with GB undergoing BVZ therapy, and thus to improve therapy response assessment.

## Methods:

Thirteen patients with GB were scanned during BVZ therapy (total of 37 MR scans). Scans were performed on a 3T MRI and included: T1WI performed before and after contrast agent injection, FLAIR, DTI, dynamic susceptibility contrast (DSC) imaging and MRS. Preprocessing included calculation of the perfusion and diffusion maps, data realignment, inhomogeneity correction, skull stripping, and smoothing. Normalized images and maps were obtained relative to the contralateral normal appearing white matter (NAWM). Hyperintense FLAIR and T1W enhancement signal areas were identified using a semi-automatic method<sup>5</sup>. The target area for segmentation was defined as the non-enhancing hyperintense FLAIR area. Unsupervised segmentation was performed using FSL FAST tool<sup>6-7</sup>. The input data consisted of 3 maps: MD and cerebral blood flow and volume (CBV/CBF), and the number of clusters (k) was set to five. The resulting clusters, obtained from all subjects, were further classified into 3 groups based on their relative (r) CBV value and referred to as different tissue types: rCBV<1 as vasogenic edema<sup>8</sup> (VasoE); 1<rCBV<1.5 as intermediate cluster (IM); and rCBV >1.5 as active tumor (ActiveT).

Figure 1



## Results and Discussion:

**Segmentation Results:** Figure 1 shows a scatterplot of the relative rCBV, rCBF and rMD cluster values obtained from all subjects. The 3 clusters differed significantly from each other ( $p<0.001$ ) by their rCBV and rCBF values (Table 1).

	rMD	rCBV	rCBF	rCh/Cr	rNAA/Cr
VasoE	1.40±0.23	0.68±0.19*	0.64±0.22*	1.30	1.03
IM	1.38±0.24	1.21±0.14*	1.16±0.21*		
ActiveT	1.40±0.21	1.82±0.24*	1.72±0.26*	1.53	0.60

MRS data obtained from 3 patients support the segmentation results (Table 1, values are relative to NAWM). As expected, the ActivT shows a more highly malignant pattern with higher Ch/Cr and lower NAA/Cr ratios compared to the VasoE.

**Follow up of treatment with BVZ:** Longitudinal data obtained from all subjects is shown in Fig. 2. In the first scan (week 2), performed after BVZ therapy, substantial reductions were detected both in the T1W enhanced (blue) and the T2W hyperintense areas (black), in all patients (Fig. 2A). However within the hyperintense T2 areas, a trend of increase in the tumor related components (IM + ActiveT, dashed line) was observed along with the decrease in the VasoE component (solid line).

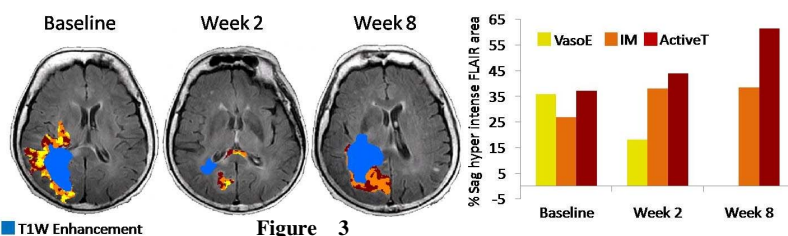
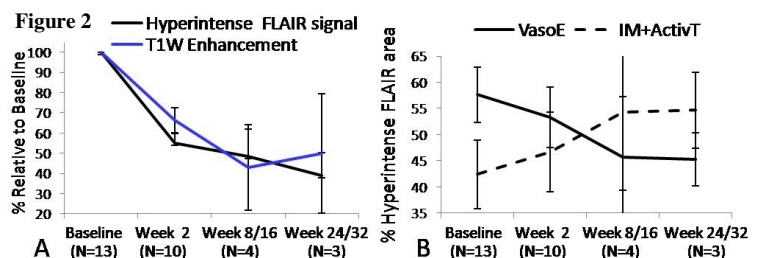


Figure 3 shows data obtained from one patient with GB scanned longitudinally along BVZ therapy. In this patient, the volume of the hyperintense FLAIR area was reduced at week 2 (36%) and returned to its initial size at week 8. However, while the VasoE (yellow) completely reduced at week 8, the volume of the tumor related components (IM+ActiveT, orange and red) increased.

## Conclusion:

In this study, hyperintense FLAIR area segmentation was performed in patients with GB following BVZ therapy. Findings of this study support previously reported studies showing a shift to an infiltrative phenotype of tumor progression in GB following treatment with BVZ. The proposed segmentation method may improve therapy response assessment in patients following BVZ therapy.

**References:** <sup>1</sup>Groot et al. Neuro Oncol, 2010; <sup>2</sup>Marc Med Insights Oncol, 2011; <sup>3</sup>Whitney et al. Curr Neurol Neurosci Rep, 2011; <sup>4</sup>Zuniga et al. J Neurooncol 2010; <sup>5</sup>Artzi et al. Eur J Radiol. 2011; <sup>6</sup><http://www.fmrib.ox.ac.uk/fsl/>; <sup>7</sup>Zhang et al. IEEE, 2001; <sup>8</sup>Kaal et al. Curr Opin Oncol. 2004.