

Investigation of vascular MRI (ASL and SWI) in complement to RANO criteria to characterize anti-angiogenic therapeutic response of glioblastomas

Slim Fellah¹, Olivier Chinot², Nadine Girard^{1,3}, Maxime Guye¹, and Virginie Callot¹

¹Centre de Résonance Magnétique Biologique et Médicale (CRMBM), CNRS / Aix-Marseille Université, Marseille, France, ²Service de Neurochirurgie, Hôpital de la Timone, AP-HM, Marseille, France, ³Service de Neuroradiologie, Hôpital de la Timone, AP-HM, Marseille, France

Introduction:

Glioblastoma Multiforme (GBM) is the most common, aggressive and angiogenic subtype of malignant glioma. New therapies involving anti-angiogenic agents are therefore now part of the therapeutic protocol and they have been shown to improve response and survival in patients with recurrent GBM (1). Currently, radiologic assessment of tumor evolution after treatment is based on the RANO criteria which include T₁ post-gadolinium, FLAIR and T₂ images (2). However, these morphological parameters may be limited by subjective evaluation and thresholds or measurements in the variation of T₂ and FLAIR hypersignal may need to be defined.

New MR markers thus need to be found to provide better and earlier information on the tumor response. In this study, we performed longitudinal MR follow-up of GBM treated with anti-angiogenics using a multimodal MR protocol. The investigations particularly involved arterial spin-labeling (ASL) and susceptibility weighted imaging (SWI). Both sequences provide vascular information that may be particularly appropriated to evaluate the anti-angiogenic response.

Materials and Methods:

Eight patients (57±15 years) with pathologically proven GBM and a minimum of 4 follow-ups were examined, either at 1.5 or 3T system, before treatment (D0), and regularly after an anti-angiogenic treatment (bevacizumab). The multimodal MRI protocol included 3D pre- and post-contrast T₁-weighted MRI, FLAIR, 3D SWI (TR/TE 27/20ms, matrix 192*256, slice thickness 1mm) and ASL perfusion MRI (PICORE-Q2PS, TR/TE/TI1/TI2 2500/11/700/1800 ms, matrix 64*64, slice thickness 5mm, 15 slices). All MR images (all follow-ups and all MR modalities) were co-registered by using SPM5 software (Wellcome Trust Centre for Neuroimaging, UK). Healthy and tumoral ROIs were outlined manually for each slice. Abnormal regions in the tumoral ROI were automatically determined based on thresholds derived from the healthy control area ($\text{threshold}_{\text{abnormal}} = (\text{mean} + 2 * \text{stdev})_{\text{healthy area}}$), and an index of aggressiveness was defined as (abnormal area x abnormal value ÷ contralateral value), using an algorithm developed with IDL (ITT Visual Information Solutions, USA).

Results:

Three main patterns of response, illustrated on fig.1, were identified: 1) Non-responders (n=3 patients) presented an increase of all MR parameters and this was in agreement with RANO criteria. 2) Pseudo-responders (n=2) were considered as responders according to RANO during the first months after the beginning of the treatment (decrease in the contrast-enhanced areas, FLAIR and T₂ hyperintensities), while both ASL and SWI showed a progressive increase with time. Contrast-enhanced and FLAIR area then dramatically increased, in agreement with failure of the treatment. 3) Responders (n=3) showed a decrease in the contrast-enhanced and FLAIR areas, in agreement with RANO, and discordant evolutions of ASL and SWI indexes.

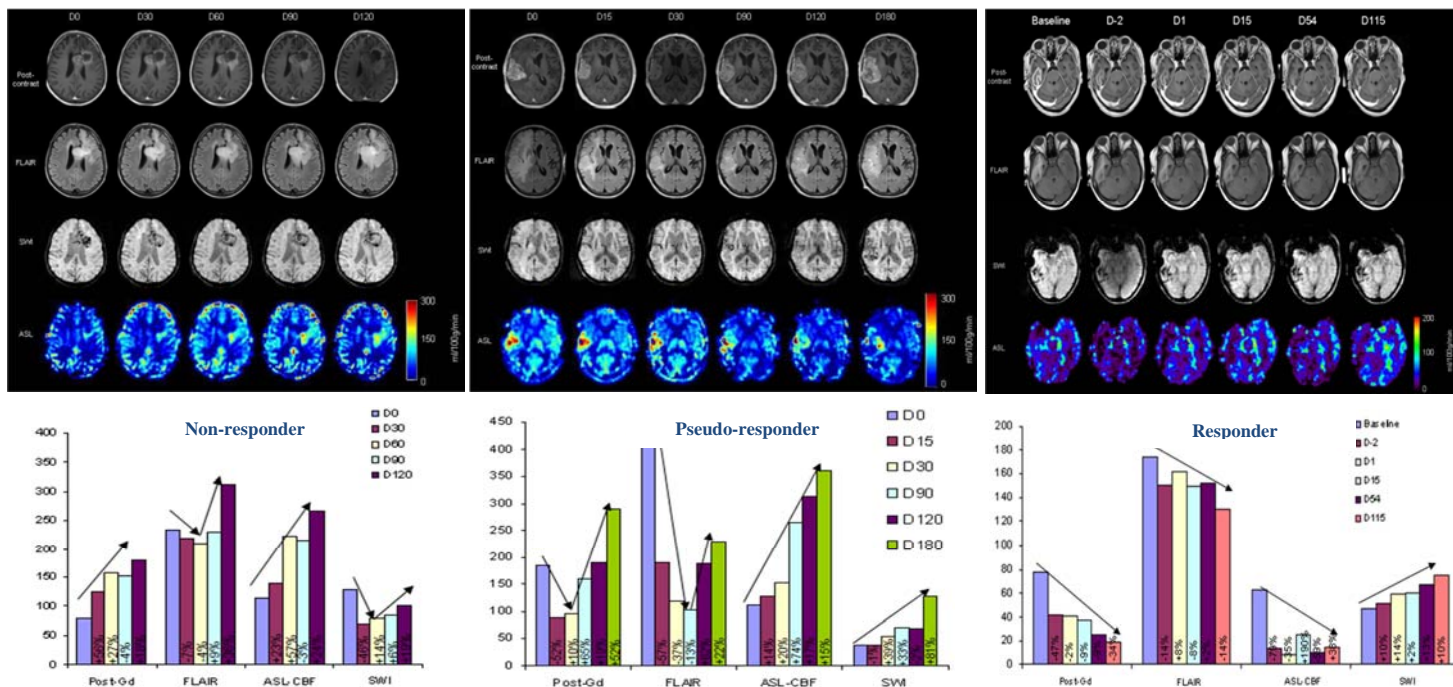


Fig1: Tumor changes on post-contrast T₁ MRI, FLAIR, SWI and ASL and the corresponding tumor aggressiveness indexes measured during the longitudinal follow-up of three representative patients: Non responder, Pseudo-responder and Responder. Values in % represent variation of aggressiveness between 2 consecutive exams.

Discussion:

In this study, ASL perfusion MRI and SWI were investigated as biomarkers of antiangiogenic therapy, in addition to RANO criteria. Both ASL and SWI-derived indexes increased in the absence of response or in case of pseudo-response, in coherence with tumor aggressiveness. The evolution observed in the 3 patients characterized as responders was less obvious (discordant ASL and SWI, increase of one/decrease of the other and vice versa) and may suggest latent evolution of the tumor before recurrence (all patients recurred after 200 days). From our point of view, the parameters derived from ASL and SWI could be considered as early indicators of disease progression and they may help to prematurely predict tumor response to anti-angiogenic therapies. These preliminary findings need of course to be confirmed in larger patient series.

References: (1) Friedman HS et al., J. Clin. Oncol. 2009;27(28):4733-40. (2) Wen PY et al., J. Clin. Oncol. 2010;28(11):1963-72.