

# Relationship between optic radiation microstructure and visual function in adolescents born extremely preterm or extremely low birth weight

Claire E Kelly<sup>1,2</sup>, Jeannie LY Cheong<sup>1,3</sup>, Carly Molloy<sup>1</sup>, Peter J Anderson<sup>1</sup>, Alan Connelly<sup>4</sup>, Lex W Doyle<sup>1,3</sup>, and Deanne K Thompson<sup>1,2</sup>

<sup>1</sup>Murdoch Childrens Research Institute, Parkville, Victoria, Australia, <sup>2</sup>University of Melbourne, Parkville, Victoria, Australia, <sup>3</sup>Royal Women's Hospital, Parkville, Victoria, Australia, <sup>4</sup>Melbourne Brain Centre, Heidelberg, Victoria, Australia

## Purpose

Extremely preterm (EP, <28 weeks' gestation) birth and extremely low birth weight (ELBW, birth weight <1000 g) are associated with a range of long-term visual impairments. Visual problems have been linked to various perinatal factors, however no factor consistently predicts high risk for each form of visual impairment. Diffusion tensor imaging and tractography have demonstrated that abnormal optic radiation microstructure predicts poor visual function in preterm *neonates*.<sup>1, 2</sup> The current study aimed to characterise optic radiation microstructure in EP/ELBW *adolescents* relative to normal birth weight (NBW, birth weight >2499 g) adolescents, and to investigate the relationship between optic radiation microstructure, perinatal factors and visual function in EP/ELBW *adolescents*.

## Methods

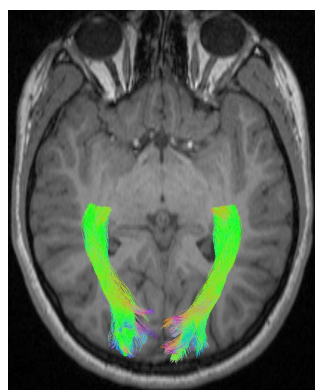
196 EP/ELBW adolescents and 144 NBW controls underwent diffusion-weighted imaging and visual assessment. Probabilistic tractography based on constrained spherical deconvolution was used to delineate the optic radiations (Figure 1).<sup>3</sup> Diffusion tensor imaging was used to obtain average optic radiation fractional anisotropy and axial, radial and mean diffusivity.<sup>4</sup> Diffusion tensor measures were compared between the EP/ELBW adolescents and NBW controls using t-tests. In the EP/ELBW group, diffusion tensor measures were correlated with clinically important perinatal variables known to influence neurodevelopmental outcome, and were compared between adolescents with impaired and normal visual acuity, binocular depth perception or vergence eye movements, using linear regression.

## Results

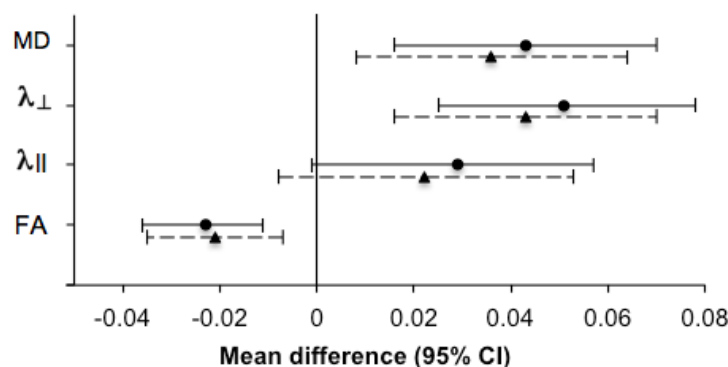
Average axial, radial and mean diffusivity were higher in the optic radiations of the EP/ELBW adolescents compared with the NBW controls (data omitted). Major neonatal brain injury (intraventricular haemorrhage grade III/IV or cystic periventricular leukomalacia) was associated with higher axial, radial and mean diffusivity in the EP/ELBW cohort (data omitted). EP/ELBW adolescents with impaired visual acuity displayed lower fractional anisotropy and higher radial and mean diffusivity compared with EP/ELBW adolescents with normal visual acuity (Figure 2). Diffusion tensor measures did not differ between EP/ELBW adolescents with impaired and normal binocular depth perception or vergence, after adjusting for clinically important perinatal variables (data omitted).

## Conclusions

EP/ELBW adolescents exhibit abnormal optic radiation microstructure compared with NBW controls, consistent with less mature optic radiation development, and/or with lasting perinatal injury. Major neonatal brain injury increases the risk of abnormalities in optic radiation microstructure in EP/ELBW adolescents, highlighting the importance of preventing severe neonatal brain injury, if possible. Furthermore, abnormal optic radiation microstructure is associated with impaired visual acuity in EP/ELBW adolescents, which may reflect less efficient or less absolute information transfer to the primary visual cortex. However, abnormal optic radiation microstructure does not directly limit binocular depth perception or vergence in EP/ELBW adolescents, suggesting that despite microstructural optic radiation abnormalities, certain aspects of visual function can develop normally. Diffusion tensor imaging provides a clearer understanding of the structural abnormalities associated with long-term visual impairment following preterm birth.



**Figure 1.** Optic radiations obtained using probabilistic tractography based on constrained spherical deconvolution.



**Figure 2.** Mean differences and 95% confidence intervals (CI) in optic radiation diffusion tensor measures between extremely preterm/low birth weight adolescents with impaired and normal visual acuity. Solid line= unadjusted analyses, dotted line= analyses adjusted for clinically important perinatal variables. MD= mean,  $\lambda_{\perp}$ = radial and  $\lambda_{\parallel}$ = axial diffusivity ( $10^{-3}$  mm<sup>2</sup>/s). FA= fractional anisotropy.

## References:

1. Bassi L, et al. Brain. 2008;131(Pt 2):573-82.
2. Berman JI, et al. Am J Neuroradiol. 2009;30(1):120-4.
3. Tournier JD, et al. Int J Imaging Syst Technol. 2012;22:53-66.
4. Behrens TE, et al. Magn Reson Med. 2003;50(5):1077-88.