

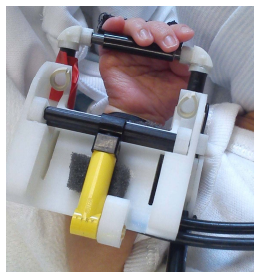
## Development of somatosensory cortical responses in the preterm period characterized with fMRI and a novel robotic device

Tomoki Arichi<sup>1,2</sup>, Alessandro Allievi<sup>3</sup>, Alejandro Melendez-Calderon<sup>3</sup>, Nora Tusor<sup>1,2</sup>, Libuse Pazderova<sup>1,2</sup>, Hilary Toulmin<sup>1</sup>, Serena J Counsell<sup>1</sup>, Etienne Burdet<sup>3</sup>, and A David Edwards<sup>1,3</sup>

<sup>1</sup>Centre for the Developing Brain, Kings College, London, London, United Kingdom, <sup>2</sup>MRC Clinical Sciences Centre, Imperial College, London, London, United Kingdom, <sup>3</sup>Department of Bioengineering, Imperial College, London, London, United Kingdom

**Background:** The human brain undergoes a dramatic and highly complex sequence of maturation during the third trimester of gestation (equivalent to the preterm period) as the underlying architecture of neural connectivity is established. This process is exemplified by the ontogeny of resting state networks, which are seen to progress from an initially fragmented (and unilateral) pattern at 30 weeks post-menstrual age (PMA), to the more complex long-range and bilateral networks characteristic to the adult brain at term equivalent age [1]. Using a combination of dedicated fMRI compatible robotic devices and an adapted data analysis pipeline, we have previously described robust patterns of functional activity in preterm infants, and have identified a clear maturational trend in the morphology of the Hemodynamic Response Function (HRF) during the neonatal period [2,3]. In this study, we aimed to characterize functional responses induced by a proprioceptive stimulus in a group of preterm infants through to term equivalent age, and hypothesized that increasing postmenstrual age would be associated with a more complex pattern of functional responses as seen during the maturation of resting state networks.

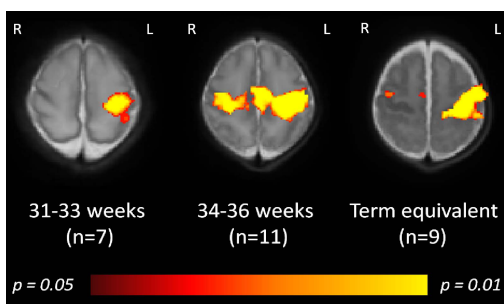
**Methods and Materials:** The study group consisted of 27 infants (range: 31+0 to 42+5 weeks PMA); of which 7 were imaged between 31-33 weeks PMA (median: 32+2 weeks); 11 were imaged between 34-36 weeks (median: 34+4 weeks); and 9 were imaged at term equivalent age (median: 41+3 weeks). Images were acquired on a 3-Tesla Philips MRI scanner (Best, Netherlands) located within the Neonatal Intensive Care Unit at the Hammersmith Hospital, London. Term infants only were sedated with oral chloral hydrate (30-50mg/kg) during image acquisition, and physiological monitoring (heart rate, oxygen saturations, and axillary temperature) was performed throughout. Written consent was taken from the parents of all study subjects prior to data acquisition. Blood Oxygen Level Dependent (BOLD) contrast fMRI images were acquired with an 8 channel head coil using a single-shot EPI sequence lasting 6 minutes and 34 seconds, with the parameters: TR/TE/FA = 1500msec/45msec/90 degrees; resolution (x/y/z) = 2.5/2.5/3.25mm; 22 slices; total 256 volumes.



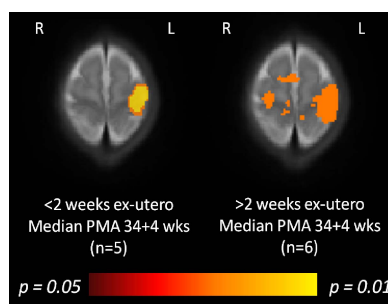
(Figure 1): The custom-made, fMRI compatible wrist robotic device, fitted to a premature infant of 34 weeks post-menstrual age (PMA).

Somatosensory cortical responses were induced with a fully automated and fMRI compatible robotic device, which was custom made to provide a safe and reproducible pattern of proprioceptive stimulation to infant subjects, and is based on similar principles to our previously described devices (*see figure 1*) [2,4]. The device was strapped onto the right forearm of each subject prior to the start of each scanning session, with the fingers and hand strapped to a bar which pivots around the natural axis of the infant's wrist flexion. Actuation of the device was achieved through a piston driven by pressurized air from the scanner control room, resulting in controlled extension and flexion of the wrist. Fine control of the pattern and timing of stimulation was possible through a DAQ card and custom software (Labview, National Instruments, Austin, TX, USA), and synchronization with image acquisition was achieved through detection of the scanner TTL pulse. A simple block stimulation paradigm of 24 seconds of 0.3Hz stimulation alternating with 24 seconds of rest was used, with a total of 8 stimulation/rest epochs presented during the acquisition period. fMRI data was analysed using tools implemented in the FMRIB software library (FSL, [www.fmrib.ox.ac.uk/fsl](http://www.fmrib.ox.ac.uk/fsl)). Functional activation maps were created using the General Linear Model as implemented in FEAT (v5.98), with the observed data defined by a convolution of the experimental design and an age appropriate HRF model [3]. The lower level statistical maps were then registered to an age specific template brain, and higher level analysis was then performed using non-parametric permutation methods as implemented in Randomise (v2.1) with threshold free cluster enhancement (TFCE).

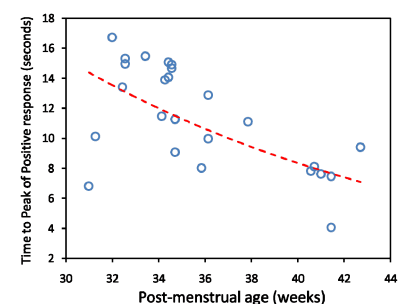
**Results:** Well localized and positive BOLD contrast responses were identified in the primary somatosensory cortices of all of the study infants with a contralateral and unilateral pattern of activation seen in the youngest study group (31-33 weeks PMA). With increasing age, a tendency towards a more bilateral pattern of response was observed, with more dispersed activity seen at 34-36 weeks PMA, and a bilateral but more localized pattern seen at term equivalent age with an additional cluster seen in the supplementary motor area (*figure 2*). In the late preterm group (34-36 weeks PMA), bilateral responses were more common in the infants who were greater than 2 weeks postnatal age, than those born within 2 weeks of scanning (*figure 3*). In addition, a maturational trend was also seen in the timing of the BOLD responses, with a decrease in the lag time to the positive peak of the response seen with increasing PMA (*figure 4*).



(Figure 2): A tendency towards an increase in bilateral functional responses is seen during the premature period, progressing to a more localized but bilateral pattern at term equivalent age.



(Figure 3): Preterm infants with greater exposure to the ex-utero environment appear to show a more bilateral and complex pattern of activity.



(Figure 4): A clear maturational trend in the timing of responses is seen, with a shorter time to the positive peak of the response seen with increasing age.

**Discussion and Conclusions:** We describe a wrist robotic device which allows a systematic proprioceptive stimulus to be presented to infants inside an MRI scanner. As seen in the resting brain, developmental trends in the pattern of functional activity can be identified during the preterm period in human infants, with a tendency towards faster and more bilateral responses seen with increasing age. This maturational trend appears to be affected by exposure to the ex-utero environment, suggesting that the development of functional activity and integration with associative structures may be activity dependent during this critical time period.

**References:** [1] Doria et al. PNAS 2010; 107(46): 20015-20. [2] Arichi et al. Neuroimage 2010; 49(3): 2063-71. [3] Arichi et al. Neuroimage 2012; 63(1): 663-73. [4] Allievi et al. (*submitted to ABME*)