

Time Resolved Coronary Vessel Wall MRI using Phase-Sensitive DIR (TRAPD)

Khaled Z. Abd-Elmoniem¹, Ahmed M. Gharib¹, and Roderic I. Pettigrew²

¹National Institute of Diabetes and Digestive and Kidney Diseases, NIH, Bethesda, MD, United States, ²National Institute of Biomedical Imaging and Bioengineering, NIH, Bethesda, MD, United States

INTRODUCTION: Coronary artery wall assessment with MRI has shown a great potential as a non-radiation alternative to CT angiography for early disease preventive assessment. However, many technical challenges still hinder coronary wall imaging for routine clinical utilization. These challenges include image suboptimal image quality and degradation due to aperiodic intrinsic cardiac and chest wall respiratory motions and residual motion due to uncompensated heart-rate variability. The purpose of this study was to 1. develop a time-resolved acquisition of phase-sensitive DIR (TRAPD) coronary vessel wall MRI technique that overcomes the loss of the orthogonality in single-frame imaging due to uncompensated residual motions, 2. assess the associated improvement in coronary wall imaging success rate relative to that of single-frame imaging, and to 3. investigate the ability of TRAPD to show a difference in vessel wall thickness between healthy subjects and subjects with risk factors for coronary artery disease (CAD).

THEORY: A conventional DIR preparation pulse as shown in Fig. 1 consists of a non-selective inversion directly followed by a slice-selective re-inversion of the magnetization at the anatomic level of interest and imaging after a specific nulling time TI^* (1). Oftentimes, however, heart rate changes and bulk motion occurs due to the extended stay inside the scanner. In addition, rest periods vary in time and duration with heart rate and from one arterial segment to another. These uncertainties may conveniently be overcome if black-blood imaging is enabled at several time-points during the rest period. Phase-sensitive DIR sequence is modified in this work to acquire several successive frames. Each frame is then reconstructed into phase-sensitive DIR sign-preserved magnitude image (2). The cine-fashioned images will capture the changes in coronary wall position and angulations during the rest period and will then permit more accurate selection of the image with optimal position and angulations and hence measurement.

METHODS: A 3T single-slice time-resolved free-breathing PS-DIR (TRAPD) coronary vessel wall imaging sequence was implemented, validated in a flow phantom using a plastic tube with a lumen-diameter of 3.2mm, a wall-thickness of 1.6 mm, and tap water ($T1 \approx 3200$ ms) flowing at a constant velocity of 25cm/s. The tube was embedded in agarose gel ($T1 \approx 1200$ ms). A TRAPD series of 10 consecutive images of a transaxial slice perpendicular to the tube was acquired with incremental inversion times ($TI = 25, 100, 150, \dots, 250$ ms). The spiral readout consisted of 22 interleaves using an RF excitation angle $\alpha = 45^\circ$ and an acquisition window of 18 ms for each. The spatial resolution was $0.66 \times 0.66 \times 8.0 \text{ mm}^3$ (FOV = $200 \times 200 \times 8 \text{ mm}^3$, matrix = 288×288). The re-inversion slice thickness was 15mm. Images were reconstructed offline with PS-DIR algorithm and lumen-agarose contrast was measured in all frames.

The proximal right coronary arterial wall was imaged using 3 to 5 cine-image measurements in 26 subjects with at least one Framingham CAD risk factors and 12 healthy subjects without history or risk factors for CAD. A fixed imaging inversion time $TI = 200$ ms for the first image and a temporal resolution $Tr = 25$ ms between subsequent frames. The spiral readout consisted of 20 interleaves, an acquisition window of 20ms, $TE/TR = 2.1$ ms/IRR interval, and the spatial resolution $0.69 \times 0.69 \times 8.0 \text{ mm}^3$ (FOV = $200 \times 200 \times 8 \text{ mm}^3$, matrix = 288×288). Wall thickness was automatically measured, and qualitative and quantitative comparisons were made between TRAPD and single-image wall measurements

RESULTS: Time resolved coronary vessel wall imaging using TRAPD successfully restored the negative polarity of lumen signal and enhanced lumen-wall contrast in the cine images in flow-phantom (Fig. 2a). Lumen-agarose contrast was substantially improved in all frames as shown in Fig. 2b in comparison to modulus-magnitude images. Imaging also restored lumen-wall contrast in both normal and subjects with coronary risk factors as shown in the example in Fig. 3. The acquisition and utilization of the additional frames increased the cumulative success rate of acquiring at least one adequate-quality image from 76% in single-image acquisitions to over 90% when five frames were acquired. Utilizing multiple consecutive frames in calculations achieved more separation between the normals' and patients' mean wall thickness values, and with more precision demonstrated by a narrower standard deviation. The difference in vessel wall thickness between the two subject groups was statistically significant ($p < 0.05$) when using TRAPD (1.07mm vs. 1.46mm; 36% increase) compared to single-frame DIR imaging (1.24mm vs. 1.55mm; 25% increase) as shown in Fig. 4.

CONCLUSION: In this work, fast time-resolved phase-sensitive DIR imaging was implemented to improve the success rate of coronary arterial wall imaging at 3T inclusive of and imaging slices orthogonal to longitudinal axis of the vessel. TRAPD has also resulted in coronary wall thickness measurements that demonstrate a more distinct difference between healthy and patient populations.

REFERENCES: (1) Fleckenstein JL et al. "Fast short-tau inversion-recovery MR imaging." *Radiology*. 1991;179(2):499-504. (2) Abd-Elmoniem KZ et al. "Phase-sensitive black-blood coronary vessel wall imaging." *Magn Reson Med*. 2010;63(4):1021-30.

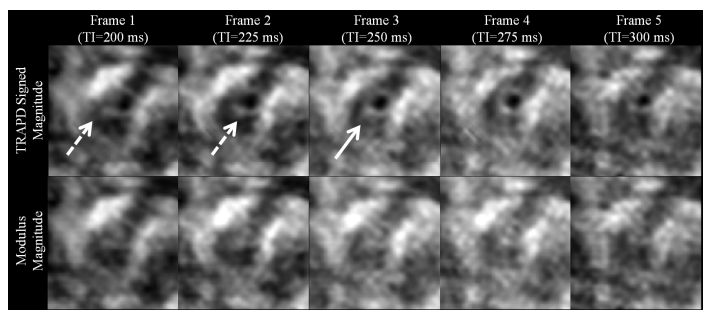


Fig. 3: TRAPD (top row) and conventional modulus images (second row) of a CAD patient. Dotted arrows denote the frames with suboptimal quality and angulation. Solid arrow denotes the frame with the thinnest wall thickness measurement.

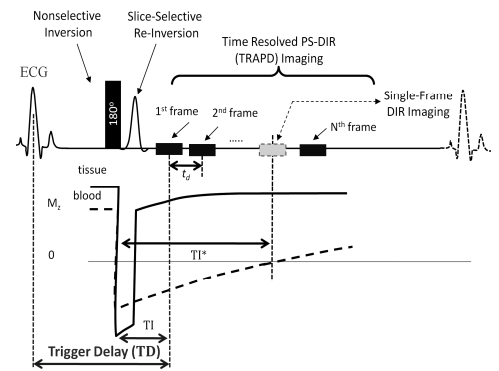


Fig. 1: DIR pulse sequence. TI^* is the time when blood magnetization is nulled. In PS-DIR, imaging starts at $TI < TI^*$. Multiple PS-DIR black-blood slices can be acquired with $CNR \geq CNR$ of DIR.

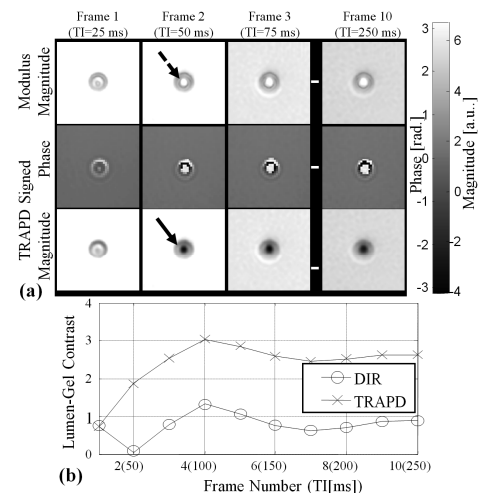


Fig. 2: TRAPD Phantom images and contrast using incremental TI ranging from 25 ms to 250 ms. (a) Modulus, phase, and TRAPD signed-magnitude images. (b) DIR and TRAPD Tissue-lumen contrasts

wall thickness vs. number of used phases

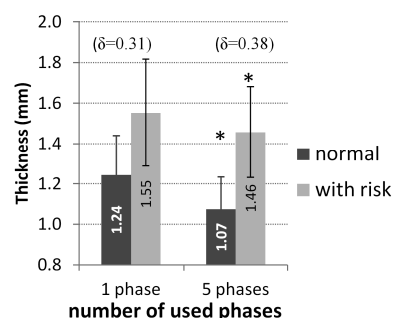


Fig. 4: Strain curves for phantom (a) and in-vivo (b) experiments.