

MR-PET Respiration Compensation Using Self-Gated Motion Modeling

Robert Grimm¹, Sebastian Fürst², Isabel Dregely², Stephan Nekolla², Sibylle Ziegler², Simon Bauer³, Dominik Nickel³, Berthold Kiefer³, Joachim Hornegger¹, Markus Schwaiger², and Tobias Block⁴

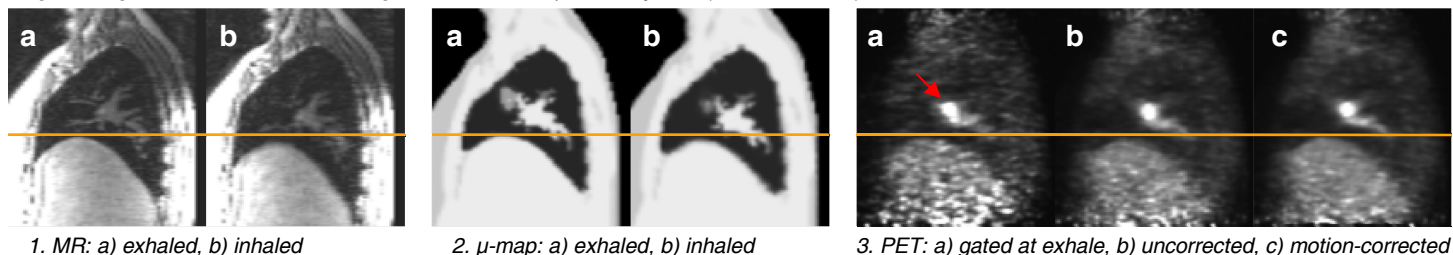
¹Pattern Recognition Lab, FAU Erlangen-Nuremberg, Erlangen, Germany, ²Department of Nuclear Medicine, Technische Universität München, Munich, Germany, ³Siemens Healthcare, Erlangen, Germany, ⁴Department of Radiology, NYU Langone Medical Center, New York City, NY, United States

INTRODUCTION: Accurate localization and uptake quantification of lesions in the chest and abdomen using PET imaging is challenging due to the respiratory motion occurring during the exam. With scan times of up to 20 minutes, suspending the respiration is not feasible while respiratory gating approaches reduce scan efficiency and, thus, lead to increased noise or excessive scan times. The advent of simultaneous MR-PET systems promises new ways to monitor and compensate for respiratory motion without exposing the patient to additional radiation. Previous work proposed the use of fast 2D or 3D acquisitions^{1,2,3,4} to derive a motion model for the purpose of PET motion correction. Here, we present first in-vivo results employing self-gated, retrospectively binned reconstructions of a continuous 3D radial stack-of-stars GRE acquisition for accurate motion modeling. The model is used to compute appropriately deformed attenuation correction μ -maps for different breathing positions. These μ -maps are then used to reconstruct a set of gated PET images from data binned according to the MR-derived self-gating signal. Finally, the gated PET images are fused into a single, respiration-compensated image using the motion model.

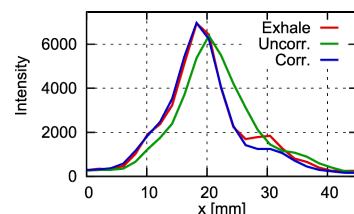
THEORY: The self-gating signal and motion model are derived from data acquired using a 3D radial stack-of-stars GRE sequence with golden-angle sampling. This trajectory continuously samples the center of k-space, which allows for detection of respiratory motion^{5,6}. By grouping the acquired MR raw data into N_b different bins according to the respiratory phases of the self-gating signal, image volumes at different levels of respiration are reconstructed. Using non-rigid registration algorithms, two sets of motion fields can then be estimated in the form of a deformation that describes the displacement of every voxel during respiration. The first set of deformations D allows warping a volume from exhalation to the other phases, while the second, inverse set D^{-1} warps a given volume to the exhaled state. In the first correction stage, the deformations D are applied to the μ -map, which is acquired in a breath-hold at exhale position, to obtain μ -maps for the other respiratory phases. Then, the MR-derived self-gating signal is used to sort the simultaneously acquired PET list-mode data, yielding a binning of N_b PET data sets, which are then reconstructed using the matching μ -maps. In the second stage, the gated PET images are fused by applying the respective inverse deformations D^{-1} to warp them to end-exhale position and by finally averaging over all volumes.

METHODS: In-vivo data was acquired using an integrated MR-PET system with 3 Tesla (Biograph mMR, Siemens Healthcare, Erlangen, Germany). Written informed consent was obtained from an oncologic patient with a lung lesion (f, 58 y, 82 kg). The PET scan was started 148 minutes after the administration of ¹⁸F-FDG (401 MBq). The μ -map was generated from a 20 s breath-hold scan at end-expiration with a 3D Dixon GRE sequence. Afterwards, MR and PET data were acquired simultaneously over 12 min. The 3D stack-of-stars sequence acquired 3296 radial angles at a base resolution of 256 pixels and covering 145 coronal slices (50% slice resolution, 5/8 partial Fourier, 10% slice oversampling), which results in a spatial resolution of $1.6 \times 1.6 \times 1.7 \text{ mm}^3$. The data sets were reconstructed using $N_b = 5$ bins and were registered with the FastSymmetricForcesDemons implementation⁷ included in the ITK framework. All PET images were reconstructed using the vendor-provided 3D ordered-subset expectation maximization (OSEM3D) algorithm (3 iterations, 21 subsets, 172×172 matrix, 4 mm Gaussian post-reconstruction filter).

Figure: Sagittal reformatted slice through lesion near left pulmonary vein (red arrow in 3a).



RESULTS: The self-gating signal enabled calculating retrospectively gated MR and PET reconstructions with highly consistent respiratory phases. As shown in Fig. 1a/b, the liver dome is displaced by approximately 10 mm between end-exhale, marked by the orange line, and end-inhale. Fig 2a/b shows that this motion is reflected well in the set of deformed μ -maps. A lesion near the left pulmonary vein (red arrow in Fig. 3a) was found to move by approx. 6 mm in head-foot direction in the gated PET reconstructions. Compared to the images of the bin at end-exhale (3a), the nodule appears slightly elongated and shifted by ~ 3 mm in the uncorrected reconstruction (3b), due to motion blur. With corrected μ -maps and after image fusion (3c), the lesion position matches the gated reconstruction. A plot of the lesion profile is displayed in Fig. 4. Moreover, motion correction significantly reduced the blur of the liver dome. The SNR (mean over standard deviation) in a $7 \times 7 \times 7$ voxel volume in the liver is about 2.56 times higher in the motion-corrected reconstruction than in the end-exhale gated reconstruction.



4. Lesion profile in gated, original, and motion-corrected images

DISCUSSION AND CONCLUSION: These first in-vivo results demonstrate that respiratory motion compensation for PET/MR is feasible using self-gating from continuous radial MRI acquisitions without additional physiological signal sensors. Significant improvement of the lesion localization was achieved with clear SNR improvement over straightforward gating of the PET data. Further SNR improvement may be achievable by integrating the motion modeling already into the PET reconstruction⁸. A limitation of the current approach is that during the PET scan only the T1-weighted MR image contrast is obtained. Therefore, future work will focus on shortening the MR scan needed for generation of the motion model and deriving a suitable physiological-signal surrogate to gate the PET acquisition, potentially using the PET data itself^{9,10}. This will enable acquiring complementary MR contrast information within the same exam time while the motion model can still be applied to correct the PET images.

REFERENCES:

- [1] Bürger et al. IEEE TNS 59, p1967, 2012.
- [2] Chun et al. J Nucl Med 53, p1284, 2012.
- [3] Würslin et al. #0147, ISMRM 2012.
- [4] Fieseler et al, A dynamic thorax phantom for the assessment of cardiac and respiratory motion correction in PET/MRI. Nucl Instrum Methods Phys Res A, in press, 2012.
- [5] Grimm et al. #0598, ISMRM 2012.
- [6] Lin et al. MRM 60, p. 1135, 2008.
- [7] Vercauteren et al. The Insight Journal, 2007.
- [8] Lamare et al. Phys Med Biol 52, p5187, 2007.
- [9] Büther et al. J Nucl Med 50, p674, 2009.
- [10] Schleyer et al. Phys Med Biol 54, p1935, 2009.