

Non-invasive assessment of cardiac metabolic alterations following LAD occlusion using hyperpolarized 13C imaging

Angus Z. Lau^{1,2}, Albert P. Chen³, Yiping Gu¹, Jennifer Barry¹, Nilesh R. Ghugre^{1,2}, Graham A. Wright^{1,2}, and Charles H. Cunningham^{1,2}

¹Imaging Research, Sunnybrook Health Sciences Centre, Toronto, Ontario, Canada, ²Department of Medical Biophysics, University of Toronto, Toronto, Ontario, Canada, ³GE Healthcare, Toronto, Ontario, Canada

Introduction. Accurate assessment of myocardial viability early following acute myocardial infarction (AMI) remains a critical challenge in cardiology. To evaluate new therapies intended to salvage tissue in the “area at risk” after reperfusion, it will be important to differentiate between viable tissue that eventually dies, viable tissue that survives, and dead tissue. Previous 13C MRS studies have shown that alterations in metabolic substrate usage occur following induction of ischemia [1,2]. In this study, hyperpolarized 13C imaging was used as a tool to monitor longitudinal metabolic changes following AMI of different severities in vivo in a porcine ischemia-reperfusion model.

Methods. Female Yorkshire pigs (n=6, wt = 28±3 kg) were prepared as previously described [3] and subjected to 45 min (n=3) or 90 min (n=3) balloon LAD occlusion, followed by reperfusion. The animals were scanned using a 3T GE MR750 scanner with a 13C transmit volume coil and a dual-tuned ¹H/¹³C receive-only surface coil (Rapid Biomedical). A HyperSense DNP polarizer (Oxford Instruments) was used to polarize 230 mg samples of [1-¹³C]pyruvic acid (Sigma-Isotec). Imaging was performed 2 days and 1 week following reperfusion. Pyruvate, bicarbonate, and lactate were imaged using a single-shot dual-gated time-resolved 13C sequence enabling whole-heart coverage [4]. Short axis images were acquired at end-expiration in diastole (6 slices, 24 breaths/min, TR = 2.5 s, Tread = 32 ms (single-shot), Thk/Spc = 10/1 mm, FOV 36cm, in-plane res. 10x10 mm²). Data acquisition started ~10 s after the beginning of the 15 s intravenous infusion of 15 mL of 160 mM pre-polarized [1-¹³C] pyruvate. A SSFP sequence in cine mode was used for functional assessment. A contrast-enhanced IR-GRE sequence was used for infarct assessment. ROIs were contoured in apical myocardium corresponding to delayed enhancement (“infarct”), in mid-chamber myocardium corresponding to non-enhancing tissue (“remote”), and in the left ventricle (“LV”). Metabolic ratios indexing PDH flux and myocardial lactate, respectively, were computed by dividing maximum mean bicarbonate (bic) and lactate (lac) signals by maximum mean LV pyruvate for each animal.

Results and Discussion. Representative short axis images in myocardium subjected to 45 and 90 min LAD occlusion are shown in Fig. 1. In the 45 min group, CINE MR revealed antero-septal wall motion defects at day 2 with returns to baseline at 1 week. IR-GRE revealed small antero-septal hyperintense regions near the apex. The 13C images showed a slight reduction in myocardial bicarbonate within the infarct core, with a return to baseline levels at 1 week. In the 90 min group, CINE MR revealed antero-septal akinesis which did not resolve at the 1 week time point. IR-GRE revealed severe transmural infarction (with microvascular obstruction at day 2) consistent with 90 min LAD occlusion [3]. The 13C images showed a large reduction in infarct core bicarbonate signal which persisted at the 1 week time point. Fig. 2 shows infarct sizes and metabolic ratios computed for each group and at each time point. Significant differences in infarct size (region of delayed enhancement) were observed between the 45 min and 90 min groups at both time points. Significant differences in HP bicarbonate in the core of the infarct were observed between both groups at both time points. We also observed a trend towards increased myocardial lactate with increasing occlusion time in remote regions (i.e. in the peri-infarct “area-at-risk”) when comparing the two groups at the early 2 day time point but the differences were not significant. We speculate that the variable lactate signal following LAD occlusion may be due to a combination of tissue viability, anaerobic glycolytic metabolism, and inflammatory processes, either via infiltrating immune cells or by native cardiomyocytes subjected to inflammatory cytokines, which could portend poorer prognosis including progression toward heart failure.

Conclusions. Cardiac metabolic changes following AMI were investigated in animals subjected to 45 and 90 min LAD occlusion using hyperpolarized 13C metabolic imaging. The bicarbonate signal within the region exhibiting delayed gadolinium enhancement was significantly different between the two groups at both time points. The 45 minute group showed a modest decrease in bicarbonate at day 2, which resolved at 7 days, while the 90 minute group showed strongly attenuated bicarbonate at both time points.

References. 1. Merritt ME et al. *MRM* 2008;60(5):1029-36. 2. Golman K et al. *MRM* 2008;59(5):1005-1013. 3. Ghugre NR et al. *MRM* 2011;66:1129-1141. 4. Lau AZ et al. *MRM* 2012 Jul 3.

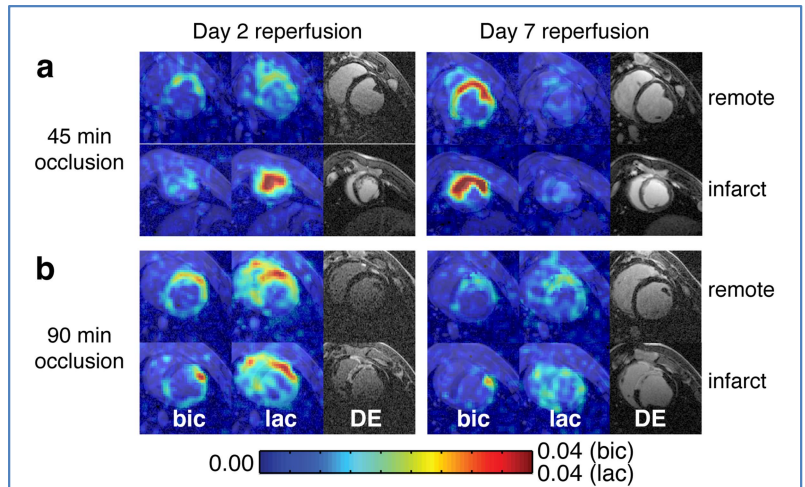


Fig. 1. Representative short axis 13C and IR-GRE images in for (a) 45 min and (b) 90 min LAD occlusion animals, at day 2 and 1 week post-reperfusion. The images are cropped to 12x12 cm².

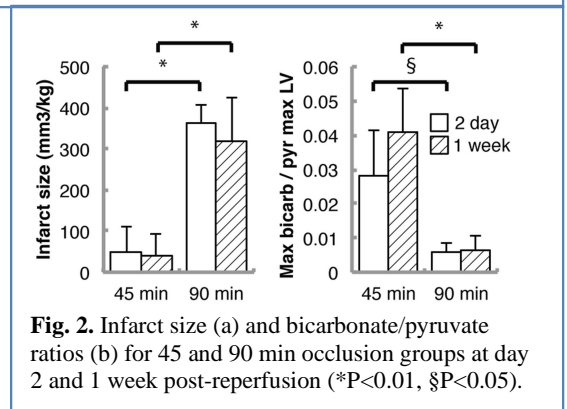


Fig. 2. Infarct size (a) and bicarbonate/pyruvate ratios (b) for 45 and 90 min occlusion groups at day 2 and 1 week post-reperfusion (*P<0.01, §P<0.05).