

## Imaging of lung structure and function in the same breath with triple nuclear (He-Xe-H) MRI

Jim M Wild<sup>1</sup>, Helen Marshall<sup>1</sup>, Xiaojun Xu<sup>1</sup>, Graham Norquay<sup>1</sup>, Steven Parnell<sup>1</sup>, Matthew Clemence<sup>2</sup>, Paul Griffiths<sup>1</sup>, and Juan Parra-Robles<sup>1</sup>  
<sup>1</sup>Academic Radiology, University of Sheffield, Sheffield, Yorkshire, United Kingdom, <sup>2</sup>Philips Medical Systems, Best, Netherlands, Netherlands

### Title: Simultaneous imaging of lung structure and function in the same breath with triple nuclear (He-Xe-H) MRI

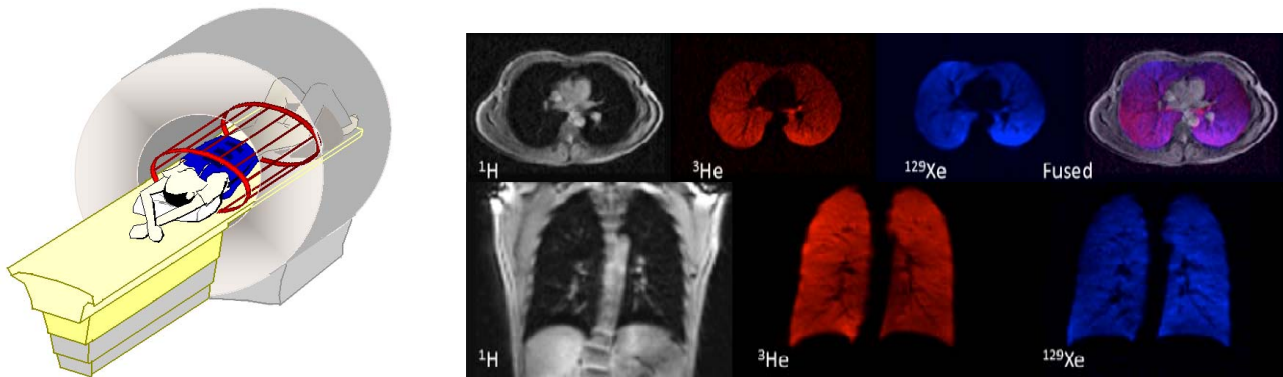
**Target audience:** Novel acquisition techniques, multi nuclear MR, lung imaging, hyperpolarised agents

**Purpose:** The purpose of this work was development of methods for the acquisition, in the same breath-hold, of lung images from two hyperpolarized gases (<sup>3</sup>He and <sup>129</sup>Xe) with simultaneous registered anatomical <sup>1</sup>H MR images of lung structure. An integrated engineering system for the rapid acquisition of triple nuclear MRI in the lungs is implemented on a standard 3T clinical MRI scanner.

**Methods:** <sup>1</sup>H, <sup>3</sup>He and <sup>129</sup>Xe MRI were performed on a 3T whole body system (Philips, Achieva, Best, Netherlands), equipped with separate frequency synthesizer boards for the respective nuclei's Larmor frequencies of 128 MHz, 97.1 MHz and 35.5 MHz. A second RF amplifier was used for transmission at 97.1 and 35.5 MHz (4kW,CPC). The <sup>1</sup>H MR signal from the thorax was acquired with the <sup>1</sup>H quadrature birdcage body transmit-receive RF coil, which was actively detuned during <sup>3</sup>He and <sup>129</sup>Xe excitation and acquisition. The inhaled <sup>3</sup>He signal from the lungs was acquired with an elliptical birdcage transmit-receive RF coil (RapidBiomedical, Germany). The <sup>129</sup>Xe MR signal from the lungs was acquired with a flexible quadrature transmit-receive vest RF coil (CMRS, USA). A schematic indicating the three nested RF coils used for <sup>1</sup>H, <sup>3</sup>He and <sup>129</sup>Xe transmit and receive in the same breath-hold is shown in Fig 1. These coils were electrically isolated ( $S_{21} < -40$  dB) from one another, which makes the coils transparent to one another's RF radiation allowing effective and safe imaging with each coil in-situ together. The coil tuning of the <sup>3</sup>He and <sup>129</sup>Xe coils when nested together and loaded with the volunteer was checked with network analyzer measurements in the magnet bore; no shift in resonant frequency or significant degradation in either coils  $S_{11}$  was observed. RF transmission and reception of the MR signals is controlled by sequential triple acquisition MRI pulse sequences developed, based on the design proposed previously for simultaneous <sup>1</sup>H <sup>3</sup>He imaging<sup>1</sup>. The sequence switches between the respective nuclear resonance frequencies to acquire 2-D spoiled gradient echo images of <sup>3</sup>He and <sup>129</sup>Xe ventilation and <sup>1</sup>H lung anatomy from the same coronal slices in the same breath-hold. Parameters for the sequences were, FOV 360 mm, 15mm slice thickness, 3 slices 15 mm gap;

**<sup>3</sup>He:** 3.75 mm pixel, partial echo, TE 0.96 ms, TR 8.1 ms, Flip angle 9°, BW/pixel 500 Hz. **<sup>129</sup>Xe:** 5mm pixel, partial echo, TE 3 ms, TR 12.0 ms, Flip angle 9°, BW/pixel 65 Hz. **<sup>1</sup>H:** 3.75 mm pixel, partial echo, TE 0.83 ms, TR 2.8 ms, Flip angle 10°, BW/pixel 500 Hz. <sup>3</sup>He and <sup>129</sup>Xe gas were polarized to 25% and 15% respectively using rubidium spin-exchange optical pumping polarisation apparatus. Imaging was performed on a healthy volunteer (female, age 27) during breath-hold following inhalation of 300 ml of <sup>3</sup>He gas mixed with 300 ml of <sup>129</sup>Xe gas and 400 ml N<sub>2</sub> gas from a 1 litre Tedlar bag (Jensen, Coral Springs, FL). Studies with <sup>3</sup>He and <sup>129</sup>Xe were performed with Institutional Ethical Review Board and regulatory approval with informed consent from the volunteer.

### Results:



**Fig.1** schematic indicating the three nested RF coils used for <sup>1</sup>H, <sup>3</sup>He and <sup>129</sup>Xe transmit and receive in the same breath-hold. **Fig 2** images of <sup>1</sup>H, <sup>3</sup>He (red), and <sup>129</sup>Xe (blue) acquired from the lungs of the healthy volunteer in the same breath, which contained 300 ml of <sup>129</sup>Xe and 300 ml of <sup>3</sup>He. The anatomical <sup>1</sup>H images demonstrate the perfect spatial and temporal registration with the <sup>3</sup>He and <sup>129</sup>Xe ventilation images as shown by the overlaid fused image (purple).

**Discussion** This method has multiple potential applications, allowing side-by-side quantitative analysis of early signs of impaired lung function from the <sup>3</sup>He and <sup>129</sup>Xe images and anatomical signs of disease from <sup>1</sup>H MRI. For a variety of lung diseases, the inherent registration of ventilation MRI to anatomical <sup>1</sup>H MRI would allow subsequent image registration to the routine radiological gold standard for lung imaging, chest CT, utilising mutual anatomical information. There are also several functional arguments for being able to perform <sup>3</sup>He-<sup>129</sup>Xe-<sup>1</sup>H MR in the same breath, in order to exploit the different physical and physiological properties of the three nuclei whilst the lungs are in the same state of physiology and inflation. One area of interest currently being explored is the use of simultaneous dual gas diffusion MR to probe lung micro-structure. When mixed in air in the proportions used here,  $D_{Xe-He-N_2} = 0.130$  cm<sup>2</sup>/s and  $D_{He-Xe-N_2} = 0.816$  cm<sup>2</sup>/s. Being able to measure diffusion of the two gases at the same time and explore different length scales in the lung micro-structure at exactly the same inflation state opens up an extra degree of freedom to diffusion measurements.

**Conclusion** An integrated RF engineering and acquisition system is demonstrated for the rapid acquisition of triple nuclear MRI in the lungs, which was implemented using a standard 3T clinical MRI scanner. The temporal and spatial registration of the images from the three nuclei is impossible to achieve in separate scans acquired in separate breaths.

### References

1. NMR Biomed. **24** (2), 130-134 (2011). **Acknowledgements** EPSRC grant #EP/D070252/1, EU FP7 Airprom.