

# High-resolution UTE MRI longitudinal non-invasive characterization of a mouse model of chronic asthma: from inflammation to bronchial remodeling assessment

Andrea Bianchi<sup>1</sup>, Annaig Ozier<sup>1</sup>, Olga Ousova<sup>1</sup>, Gérard Raffard<sup>2</sup>, and Yannick Crémillieux<sup>1</sup>

<sup>1</sup>Cardio-Thoracic Center of Bordeaux, University of Bordeaux Segalen, Bordeaux, France, France, <sup>2</sup>Centre de Résonance Magnétique des Systèmes Biologiques, University of Bordeaux Segalen, Bordeaux, France, France

## Introduction:

Asthma is a frequent complex disease which involves bronchial hyperresponsiveness (BHR), chronic inflammation of the airways and bronchial remodeling. Contrarily to other imaging techniques, proton MRI has covered only a marginal role in the study of asthma pathophysiology.

In 2012 we proposed a MRI protocol [1] which, exploiting the advantages of an ultra-short echo time (UTE) sequence, was shown to be appropriate for the quantification of the small peribronchovascular inflammation typical of the first phase of the chosen ovalbumin (OVA) model of asthma. The high quality of the images indicated the possibility of extending the protocol until the last phase of the OVA-model, in order to assess also the remodeling associated with the disease. We present here an UTE proton MRI high-resolution investigation of a chronic model of asthma in mice whose purpose is to longitudinally assess all the main hallmarks of the asthma model (including bronchial remodeling) using a fully non-invasive approach.

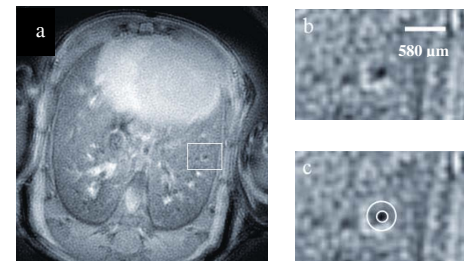
## Material and methods:

**Protocol:** Female Balb/c mice (6 weeks-old,  $22.4 \pm 0.4$  g) were used for the experimentation. Six mice received an intraperitoneal injection of 100  $\mu$ g of ovalbumin on Days 0 and 14 while the three control mice received an equivalent injection of saline solution. Mice received also an intranasal dose of 500  $\mu$ g of ovalbumin (OVA group) or saline (controls) on days 14, 27, 28 and 29, 47, 61, 73, 74 and 75 as described in Refs. [2] and [3]. The MR images were acquired on Days 0, before OVA/saline injections, and at days 38, 78 and 110. The plethysmography was performed to all the animals on days 0, 39, 79 and 111.

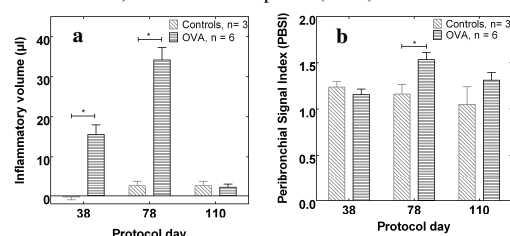
**MR acquisition:** The images were acquired with a 4.7 T Biospec 47/50 spectrometer (Bruker, Ettlingen, D), using a transmitter/receiver quadrature coil of 25 mm inner diameter (Bruker, Ettlingen, D). Mice were anesthetized with 2% isoflurane in a mixture of N<sub>2</sub>/O<sub>2</sub> (80:20) via facial mask and placed supine in a custom-built plastic holder. The temperature was kept constant using warm circulating water and the respiratory cycle was constantly monitored. For each animal 12 consecutive axial slices were acquired, in order to cover the whole lung volume. The acquisition was performed in *free-breathing* animals, using the 2D UTE sequence (804 directions/128 points, 4 averages), with a TR of 200 ms, TE of 276  $\mu$ s, FA of 30°, for a total acquisition time of about 10 minutes. The images were acquired with a FOV of 3 cm and slice thickness of 1 mm for the inflammatory volumes computation and with a FOV of 2.5 cm and slice thickness of 0.5 mm for the bronchial remodeling assessment (high-resolution images).

**Image analysis:** The images were reconstructed with in-house software implemented in IDL (RSI, Boulder, CO). The volume of the inflammation in the lungs was quantified with a semiautomatic segmentation procedure with the help of a medical image analysis software (MIPAV by JHU, US-MD), according to procedure already described in Ref. [1] and readapted from Ref. [4]. In particular, the computed volume at Day 0 (corresponding to the vessels) was subtracted to the ones computed at Days 38, 78 and 110 (corresponding to vessels and inflammation) after the OVA-challenge. In the high-resolution images, for each bronchus the bronchial lumen was manually delineated and the lumen area (LA) was measured. A ring-shaped region of interest (ROI) was then drawn around the lumen in order to measure the peribronchial signal intensity normalized by the signal measured in the muscle (PBS), as shown in Fig. 1 for an asthmatic mouse. The thickness of the ROI was chosen equal to the radius of the bronchial lumen since peribronchial infiltration was shown to grossly scatter just beyond this limit in a previous histological study using the same asthma model [2,3]. From LA and PBS, a peribronchial signal intensity index (PBSI) was computed by assigning to each of the studied bronchi a weight depending on its LA ( $PBSI = \frac{\sum (PBS \times LA)}{\sum LA}$ ).

**Plethysmography:** The plethysmography was performed with a standard whole-body plethysmograph (Emka Technologies, Paris, F). For each mouse, the measurement was performed for 3 minutes after saline nebulisation and after the nebulisation of a bronchoconstrictor (8 mg/ml solution of methacholine). The enhanced pause (Penh) values were computed for each breathing cycle and averaged over the 3 minutes measurements.



**Fig 1.** (a) Typical MRI UTE axial slice acquired in an asthmatic mouse to quantify the bronchial remodeling at day 78. (b) The zoom on an asthmatic mouse bronchus and (c) the typical segmentation procedure used to measure the LA and PBS.



**Fig 2.** Bar plots showing (a) the inflammatory volumes and (b) the PBSI at the different time points.

## Discussion:

The increase in the average inflammation volumes from day 38 to 78 is consistent with the increasing number of albumin intranasal challenges which the mice undergo between the two time-points while the interruption of the antigen administrations at day 78 triggers a slow inflammation reabsorption which culminates in the absence of differences in inflammation volumes between the two groups at the third time-point (day 110). The observed rise in the PBSI index at day 78 is coherent with the main changes which take place following the airways remodeling mechanism [2,3], as shown in Fig. 3. On the other side, the absence of a statistical difference at day 38 is consistent with several studies which showed that long protocols of 8-12 weeks are needed to initiate the bronchial remodeling process [5]. Similarly, the absence of differences at day 110 seems to suggest that the remodeling process is reversible at the end of the allergen administrations.

The bulk of evidence showed that, while the first time-point analyzed (days 38-39) is characterized only by a mild peribronchovascular inflammation and a significant BHR, the second time-point (days 78-79) presents a more extended eosinophil inflammation together with a strong peribronchial remodeling and BHR. The third time-point (days 110-111) is instead characterized by a residual BHR and probably a weak regressive airways remodeling even though further studies are required to clarify this point.

## Conclusion:

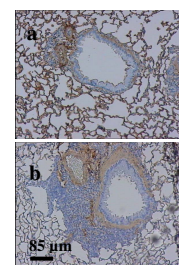
To the best of our knowledge, this is the first work which demonstrates the feasibility of non-invasive bronchial remodeling characterization in asthmatic mice using UTE proton MRI and which correlates inflammation volumes or bronchial remodeling parameters with functional data. The immediate consequence is that UTE proton MRI could be a reliable tool to monitor non-invasively the evolution of bronchial remodeling in a therapeutical drug delivery preclinical study. Such results in mice can be seen as well as a first step towards human studies with the aim of identifying MRI markers of asthma.

## References:

- [1] *Proc. Intl. Soc. Mag. Reson. Med.* 20, p. 3972 (2012); [2] *European Radiology*, 2010, 20, 128-137; [3] *Am. J. Respir. Crit. Care Med.*, 2002, 165, 108-116; [4] *Radiology*, 2008, 248, 834-843; [5] *Clinical & Experimental Allergy*, 2005, 35:1251-1253

## Acknowledgments:

This work was supported by the European Marie Curie Action PI-NET-2010-264864



**Fig 3.** Microscopic images of (a) control and (b) asthmatic mice stained bronchial sections at day 78. The increase in smooth-muscle mass (stained in brown) is one of the main changes which take place following the bronchial remodeling mechanism.