

Comparison of noncontrast FSD MRA to time resolved (TWIST) and high resolution contrast enhanced MRA of the hands in patients with systemic lupus erythematosus (SLE) and clinical vasculopathy.

Rola Saouaf¹, Zhaoyang Fan², Mariko L Ishimori³, Lindsay J Forbess³, Emmanuil Smorodinsky¹, Daniel J Wallace³, Michael H Weisman³, and Debiao Li²

¹Imaging, Cedars-Sinai Medical Center, Los Angeles, California, United States, ²Biomedical Imaging Research Institute, Cedars-Sinai Medical Center, Los Angeles, California, United States, ³Rheumatology, Cedars-Sinai Medical Center, Los Angeles, California, United States

Introduction: Systemic Lupus Erythematosus (SLE) is a multisystem autoimmune disorder with a wide range of clinical presentations, including digital vasculitis. These vasculitis lesions typically affect the hands, leading to pain, ischemia, erythema, and dermal ulceration.¹ The gold standard for imaging is digital subtraction angiography (DSA), which is invasive and has inherent complications.² Contrast-enhanced (CE) MRA has been shown to be an effective noninvasive technique but has its limitations in evaluating the hand vasculature due to small caliber vessels, and short arteriovenous transit time.^{3,4} Gadolinium contrast may also be a limiting factor in patients with decreased renal function secondary to lupus nephritis and associated risk of nephrogenic systemic fibrosis.⁵ Noncontrast (NC) MRA with Flow-Sensitive Dephasing (FSD) has shown promise in the evaluation of hand vasculature.⁶ **The purpose of this study was to investigate the feasibility of using FSD-MRA for evaluating hands of patients with known SLE vasculopathy.**

Methods: Six patients (5 F, 1 M) meeting American College of Rheumatology classification criteria for SLE with hand symptoms ranging from 3 mos to 13 yrs were prospectively recruited. Bilateral hand imaging was performed using an oblique coronal acquisition. NC FSD-MRA preceded a high-resolution CE-MRA scan (0.15 mmol/kg bodyweight MultiHance injected at 2 ml/s, 2 consecutive 18.5-sec-long post-injection measurements, TWIST for bolus timing with 0.05 mmol/kg contrast) at 1.5T (Avanto, Siemens). The optimal FSD strength or first-order gradient moment (m_1) was determined through an m_1 -scout scan.⁷ All MRA scans used two body matrix coils with the hands sandwiched between them. Spatial resolution = 0.94x0.94x0.94 mm³ (FSD-MRA), 1.3x1.3x0.9 mm³ (TWIST), and 0.82x0.82x0.82 mm³ (CE-MRA). Two radiologists reviewed MRA images in consensus for venous contamination, motion artifacts on palmar and digital stations as well as segment conspicuity and stenosis in 18 segments. Soft tissue hyperemia (CE-MRA) and depiction of 3rd terminal digits (FSD-MRA) were recorded. Patient (subjective) and physician (objective) questionnaires were utilized to document perceived digital involvement and physical findings and for comparison to MRA findings.

Results: FSD-MRA was superior to both contrast techniques in visualizing arterial segments in all regions (Table 1). No proof indicated that FSD-MRA is more susceptible to venous contamination or motion artifacts. The 3rd terminal digital arteries were better depicted by FSD-MRA (13 segments at index, 14 at middle, 14 at ring, 10 at little) compared with TWIST (2, 3, 3, 3) and CE-MRA (8, 5, 6, 6). The vascular pathology in these SLE subjects

predominantly affected the digital vasculature with sparing of palmar vessels and in relatively symmetric pattern. Hyperemia on contrast administration correlated with clinical manifestations. Soft tissue changes and edema of digits were limited in visualization on FSD-MRA. It was observed that palmar and digital arteries were barely enhanced on CE-MRA and TWIST in some cases (Fig. 1), potentially resulting in overestimation of the disease severity. This suggests limited passage of gadolinium into tiny vessels. Venous contamination significantly impaired visualization of digital vessels on CE-MRA (Fig. 2).

Discussion: FSD-MRA is a promising technique for diagnosing hand vasculopathy in SLE patients with superior image quality allowing for more confident diagnoses than CE MRA. NC FSD also has advantage in SLE patients who often have renal insufficiency. Hyperemia, which can provide additional information, is limited with NC technique but dedicated T2 FS may be added to gain similar information. Clinical findings did not completely correlate with extent of vascular involvement, suggesting other confounding factors for patient symptomatology. This is an ongoing study with increasing subjects and our preliminary data show this technique warrants further exploration.

References: [1] Rahman A et al. N Engl J Med 2008;358:929. [2] Vogelzang RL. Hand Clin 1991;7:63. [3] Connell DA et al. Radiographics 2002;22:583. [4] Brauck K et al. Eur Radiol 2007;17:183. [5] Bongartz G et al. JMRI 2007;26:1179. [6] Fan Z et al. Invest Radiol 2011;46:1. [7] Fan Z et al. Magn Reson Med 2011;65:964

	Venous		Motion		Segment Conspicuity				Stenosis			
	Palm.	Dig.	Palm.	Dig.	R.1	R.2	R.3	R.4	R.1	R.2	R.3	R.4
FSD-MRA	1.0±0.0	0.5±0.5	0.0±0.0	1.0±1.1	1.1±0.2	1.0±0.0	1.4±0.8	2.0±1.1	0.1±0.3	0.3±0.4	0.7±1.0	1.3±1.0
TWIST	0.0±0.0	0.0±0.0	0.0±0.0	0.0±0.0	1.6±0.8	2.0±1.2	2.6±1.1	3.3±0.6	0.5±0.8	1.4±1.0	1.8±1.1	2.5±0.6
CE-MRA	0.7±0.5	1.0±0.9	0.0±0.0	0.0±0.0	1.3±0.7	1.4±0.6	2.1±1.2	2.7±1.0	0.2±0.5	0.8±0.9	1.2±1.1	2.1±0.7
	(0.157)	(0.180)	(1.0)	(0.083)	(0.029)	(0.001)	(0.001)	(0.001)	(0.033)	(0.001)	(0.001)	(0.001)

Table 1. Venous signal at palmar and digital stations (0: absent - 3: affecting image interpretation). Motion at palmar and digital stations (0: absent - 3: severe and nondiagnostic). Segment conspicuity (1: good - 4: nondiagnostic). Stenosis (0: none - 3: occluded). R.1: region 1 includes radial, ulnar, arches. R.2: region 2 includes common digital arteries. R.3: region 3 includes princeps pollicis, proper thumb, radialis indicis. R.4: region 4 includes proper digital arteries. Palm: palmar; Dig: digital. The numbers in parenthesis are p values (Wilcoxon Test), and bolded numbers indicate statistical significance, i.e. p<0.05.

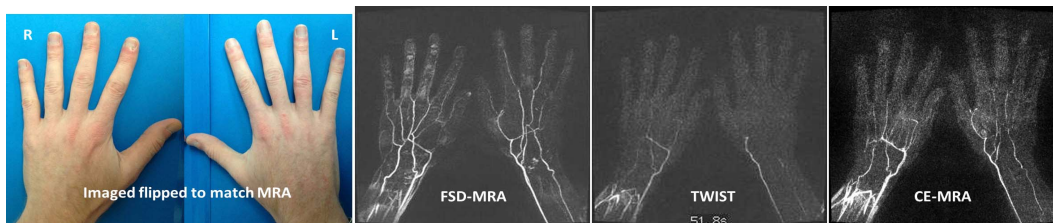


Fig. 1. Subject #3 A 29 yo male with SLE for 5 yrs and hand symptoms for < 1 year. FSD-MRA demonstrates good conspicuity and patency of the palmar vessels but significantly diminished visualization and irregularity of the digital vessels suggesting significant vascular occlusive disease. CE-MRA and TWIST sequences had fair to poor visualization, respectively, of the palmar vessels and nonvisualization of the digital vessels precluding differentiation between technical factors and clinical disease. The clinical evaluation rated 6 distal tufts (3 each hand) with findings of vasculitis.

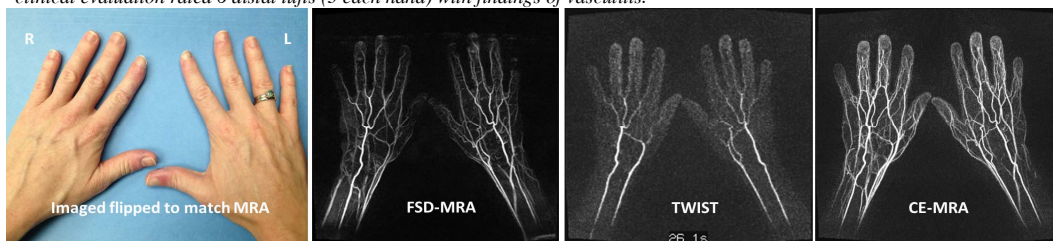


Fig. 2. Subject #6 A 33 yo female with SLE for 13 yrs and hand symptoms for 10 yrs. FSD demonstrates excellent visualization of the palmar vessels and excellent to good visualization of the digital vessels. There is mild venous contamination which does not affect the diagnostic quality of the images. TWIST images have good separation of arterial and venous phases but relatively poor opacification of digital vessels. CE-MRA has very good resolution but significant venous contamination limiting visualization of digital vessels. The patient had subjective and objective findings of vasculitis in all digits and nearly all vessels were visualized to their terminus.