

Voxel-wise repeatability of apparent diffusion coefficient in patients with newly diagnosed glioblastoma

Pavlina Polaskova¹, Kourosh Jafari-Khouzani¹, Alexander R. Guimaraes¹, Steven Stufflebeam¹, Patrick Y. Wen², Tracy T. Batchelor³, Bruce R. Rosen¹, Elizabeth R. Gerstner³, and Jayashree Kalpathy-Cramer¹

¹Radiology, Athinoula A. Martinos Center for Biomedical Imaging / Massachusetts General Hospital, Charlestown, Massachusetts, United States, ²Neuro-oncology, Brigham and Women's Hospital / Harvard Medical School, Boston, Massachusetts, United States, ³Neurology, Massachusetts General Hospital / Harvard Medical School, Boston, Massachusetts, United States

Purpose

We evaluated the repeatability of voxel-based parameters obtained by diffusion-weighted images in a cohort of patients with newly diagnosed glioblastoma enrolled in a clinical trial. Two baseline scans were acquired before the initiation of therapy to assess the variability of apparent diffusion coefficient (ADC) in the tumor. Our goal was to assess the differences on a voxel-by-voxel basis. Assessing the repeatability of voxel-based parameters is crucial for the further development of parametric maps, a proposed imaging biomarker in patients with glioblastoma and other tumors. One such biomarker, the functional diffusion map (fDM) is created by registering post-treatment to pre-treatment ADC maps and color-coding the resulting Δ ADC map according to the degree of ADC change [5,6]. Although shown to be sensitive to tumor progression, the previously proposed thresholds [3,5,6] for functional diffusion maps were based on normal appearing grey and white matter values on a 1.5T scanner. Therefore, we decided to explore the repeatability of the tumor ADC values acquired on a 3T MRI in relation to current fDM thresholds.

Methods

Thirty-five patients with newly diagnosed GBMs (age: 22–74 years, mean: 56 years) were included in this IRB approved study after signing informed consent. Two baseline scans were acquired before the treatment onset for each subject (baseline1, baseline2), typically 2-4 days apart with no intervention or change in therapy. In addition to standard anatomical MRI (T1 weighted, FLAIR, high resolution T2-SPACE), ADC maps were calculated from diffusion-weighted images with repetition-time TR=7500 ms, echo-time TE=84 ms and b-values of 0 and 700 s/mm² in 42 directions. All imaging was performed on a 3T Siemens scanner. A neuroradiologist created regions of interest (ROIs), outlining the contrast-enhancing tumor on the post-contrast T1-weighted image (CE-T1) and the FLAIR signal abnormality (FLAIR). All the diffusion-weighted images were co-registered to T2-SPACE images using non-rigid co-registration (ANTS, (<http://www.picsl.upenn.edu/ANTS/>)) to correct for potential static deformation due to susceptibility artifacts and field inhomogeneity. CE-T1, FLAIR images and their respective ROIs were also co-registered to T2-SPACE using rigid co-registration (SPM, (<http://www.fil.ion.ucl.ac.uk/spm/>)). Subsequently, baseline1 ADC maps were co-registered to baseline2 maps using rigid co-registration. All the co-registration steps were followed by visual inspection. Measures of reproducibility were assessed using intra-class correlation coefficient (ICC) and Bland-Altman repeatability coefficient (RC) [2,4]. All ADC values are reported in 10⁻³ mm²/s. All the numbers represent the median of the cohort, unless noted otherwise. The initially proposed fDM thresholds [5] (post-treatment minus pre-treatment) reported in the literature are (10⁻³ mm²/s) Δ ADC = 0.55 (red), -0.55 – 0.55 (green, stable tumor), -0.55 (blue). More recent, revised thresholds [6] are Δ ADC = 0.75 (dark red), 0.40 (red), 0.25 (light red), -0.25 – 0.25 (green), -0.25 (light blue), -0.40 (blue), -0.75 (dark blue).[6]

Results

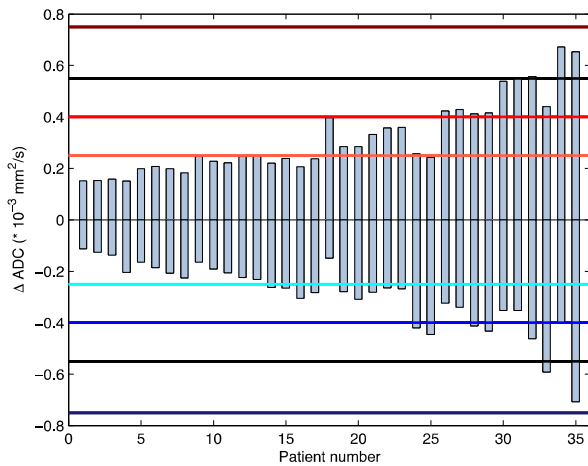


Figure 1: Each bar represents the 95 % confidence interval of an individual patient. The Y-axis denotes the Δ ADC. The black lines represent the original proposed fDM thresholds [5], the colored lines represent the revised thresholds [6]. Results shown for FLAIR ROI. Twenty-one out of 35 patients (60 %) exceed the fDM variability of a stable voxel.

Discussion

Our ICC results indicate that there is a good repeatability of ADC values on a voxel-by-voxel basis, both for CE-T1 ROI and FLAIR ROI, which supports good ROI-mean based repeatability reported in the past [1]. The thresholds that were previously suggested as a reflection of a true change in tumor cellularity were in fact based on normal appearing grey and white matter and CSF mixtures. Our data indicate that even within a relatively short interval (2-4 days typically) and with no therapeutic intervention, the variability of the tumor ADC values exceeds at least one of the proposed limits of a stable tumor in 60 % of cases, suggesting that the currently proposed absolute thresholds indicating tumor tissue change be re-evaluated. Limitations of methods based on voxel-wise differences include improper registration, shift associated with tumor volume change, and evolution of post-surgical changes.

References

1. Paldino MJ et al. J Magn Reson Imaging. 2009 May;29(5):1199-205.
2. Bland JM, Altman DG. Lancet. 1986 Feb 8;1(8476):307-10.
3. Ellingson BM et al. J Magn Reson Imaging. 2010 March;31(3):538-548.
4. Barnhart HX, Barboriak DP. Transl Oncol. 2009 Dec;2(4):231-5.
5. Moffat BA et al. Natl Acad Sci USA 2005;102:5524-5529.
6. Ellingson BM et al. Neuro-Oncology 2011 Oct; 13(10):1151-1161.

The median ICC for ADC values within the CE-T1 ROI was 0.907, for FLAIR ROI 0.904. The median RC for ADC within CE-T1 ROI was 0.340, the mean difference was 0.021, for the FLAIR ROI the median RC was 0.248 and the mean difference was 0.010.

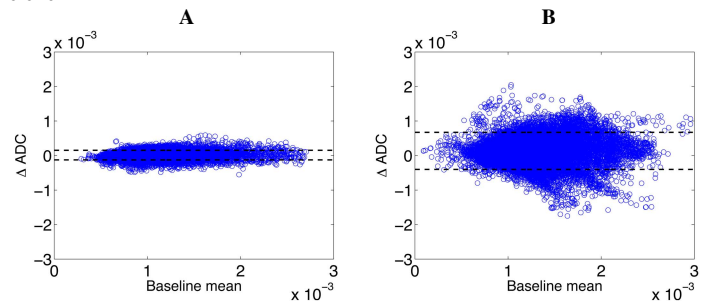


Figure 2: Bland-Altman repeatability analysis of individual voxel ADC values for a patient with low RC (A) and high RC (B) (results shown for FLAIR ROI). The dotted lines represent the 95% confidence interval.