

Clinical utility of in-vivo MRS measurements of 2-hydroxyglutarate in IDH-mutated gliomas

Changho Choi¹, Sandeep Ganji¹, Akshay Madan¹, Ralph DeBerardinis¹, Bruce Mickey¹, Craig Malloy¹, Robert Bachoo¹, and Elizabeth Maher¹
¹University of Texas Southwestern Medical Center, Dallas, Texas, United States

Target audience: Neuro-oncologists/radiologists/surgeons and MR spectroscopists in brain tumors.

Purpose/Hypothesis: Following the discovery of the production of 2-hydroxyglutarate (2HG) in gliomas with mutations in isocitrate dehydrogenase (IDH) 1 and 2 [1,2], several researchers reported *in-vivo* detection of this onco-metabolite by ¹H-MRS [3-5]. Although the role of 2HG associated with IDH mutation is well established for prognosis, how it can be used for improving the patient care is largely unknown. In order for MRS measures of 2HG to be useful as a dynamic biomarker, several basic criteria have to be met (Fig. 1). First, the 2HG measurements must be reproducible. Second, the 2HG levels must be stable over time if there is no clinical and/or radiographic evidence of tumor growth and progression. Third, the 2HG levels must rise when the tumor begins to grow or transform from low to high grade. Fourth, the 2HG levels must fall when there is tumor cell death in response to chemotherapy and/or radiation. Here we present data from 35 patients, answering to these questions.

Methods: Patient enrollment: The enrollment procedure for each patient was as follows. Patients were referred for indications: a) a new patient had a tumor mass that had radiographic characteristics of a low grade glioma (non-enhancing mass on post-Gad MRI) prior to surgical intervention; b) a patient had known grade 2 or 3 glioma and was referred for 2HG imaging at some point in the clinical course. All patients who had a surgical procedure had evaluation of tumor tissue for IDH1 and 2. Patients were scanned every 1-10 month depending on the clinical situation. **MR experimental:** The MR scan protocol included T2w-FLAIR, single-voxel MRS, and MRSI, as well as post-gadolinium (Gad) MRI, at 3T. 2HG was measured using a previously-reported PRESS TE = 97 ms [5]. For single-voxel MRS, the voxel size was 3 - 8 mL, depending on the tumor size. For MRSI, data were acquired from a 1.5 cm thick slab prescribed by the PRESS, with 1x1 cm² resolution. Following LCModel fitting, metabolite levels were estimated with reference to water at 42 M [5].

Results & Discussion: Reproducibility of 2HG measurements: We conducted test-retest 2HG MRS scans in 5 patients with 4 - 7 day intervals. Spectral patterns were well reproduced (data not shown), giving 2HG estimates from the pair scans within 0.3 mM. **2HG is stable over time in stable tumors:** Eighteen patients underwent MR scans at multiple time points during the routine clinical follow up when there was no clinical and/or radiographic evidence of tumor growth or progression. The patients had MR scans at 3 - 8 time points (median 4) with a median interval of 3 months (range 2 - 9 months). The 2HG levels were stable during the test period (Fig. 2a). A histogram (Fig. 2b) indicated that 2HG level change > 1 mM can be used for assessing tumor growth and progression. **2HG rises with tumor growth/progression:** The next goal of 2HG evaluation as a biomarker was to determine whether there was an increase in 2HG level > 1 mM at the time of clinical and/or radiographic progression. Figure 3 shows a case of a brainstem tumor which was transformed from low-grade astrocytoma to glioblastoma after several years of being stable. Baseline 2HG measurement was 3.5 mM at the

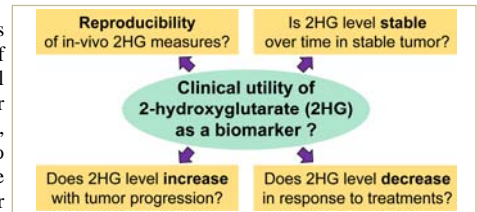


FIG 1. Diagram for the purpose of the study.

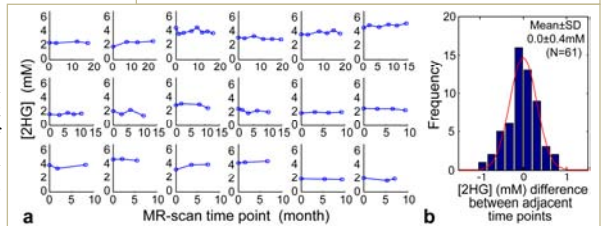


FIG 2. **2HG is stable in stable tumors.** (a) 2HG measurements over time in 18 patients when there is no clinical and/or radiographic evidence of tumor progression. (b) Histogram for 2HG level differences between adjacent time points.

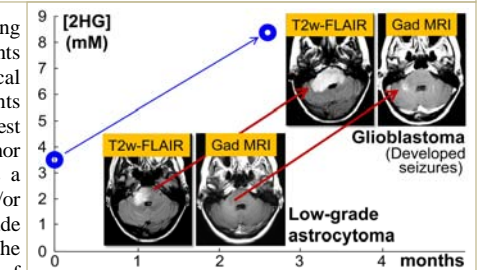


FIG 3. **Marked increase in 2HG level correlates with tumor progression.** Tumor growth and progression of a brainstem tumor over ~3 months was associated with a rise in 2HG level from 3.5 mM (CRLB 11%) to 8.4 mM (CRLB 5%). The patient was treated with chemotherapy between the scans, but did not respond.

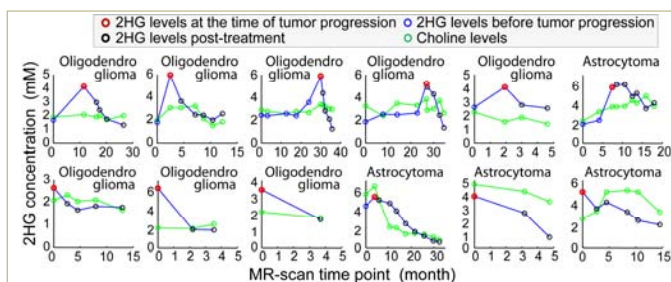


FIG 4. **Correlation of 2HG levels with progression and treatments in 8 oligodendrogliomas and 4 astrocytomas.** Each patient was treated with chemotherapy at the point of peak 2HG level (red circles). The 2HG levels fell over time as treatment continued. Choline did not show good correlation.

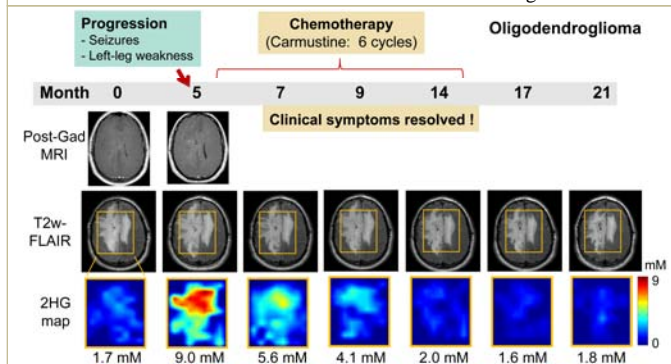


FIG 5. **A diffuse oligodendroglioma responded rapidly and completely to chemotherapy.** 2HG was highly correlated with progression and treatment effects, while post-gadolinium MRI and T2w-FLAIR did not show noticeable changes.

start of treatment. After 2 cycles of temozolomide, there was significant radiographic and clinical progression and the 2HG level had risen to 8.4 mM. A rise in 2HG (>1 mM) was detected in each of 6 patients who had objective clinical and/or radiographic evidence of progression (Fig. 4, upper panel). The highest 2HG level was associated with new enhancement on clinical MRI and/or progression of neurological symptoms, most often seizures. **2HG falls in response to treatments:** Having established that the assessment of 2HG is useful for following stable disease and was able to detect a significant change in 2HG levels with tumor progression, the potential value of 2HG as a biomarker for treatment response was investigated in a series of patients who underwent treatment at the time of progression. In Fig. 4, patients in the upper panel were treated at the time of progression following a period of observation, while patients in the lower panel were treated at the time of diagnosis. In each case, there was a clear decrease in 2HG levels with treatment. Interestingly, the decrease in 2HG was more rapid in oligodendrogliomas than in astrocytomas, suggesting different rates and/or mechanisms of cell death in the tumor subtypes. Figure 5 shows a case of an oligodendroglioma patient who had clinical symptoms 5 months after being enrolled in the study. The patient underwent chemotherapy and the symptoms completely resolved. Post-Gad MRI showed no enhancement at the time of progression (month 5). 2HG MRS scans were undertaken at 7 time points over 21 months. T2w-FLAIR images did not show noticeable changes. However, 2HG levels were highly correlated with the clinical symptoms and response to treatments. The 2HG level, which was initially 1.7 mM, increased to 9 mM at the time of clinical progression, and decreased to 5.6 mM ~2 months after the initial chemotherapy. Subsequent scans with chemotherapy showed further reduction, followed by stable levels at < 2 mM.

Conclusion: 2HG is a remarkably sensitive biomarker for monitoring progression and response to treatment in patients with IDH-mutated gliomas.

References: 1. Dang *et al.* Nature 2009;462:739-744. 2. Ward *et al.* Cancer Cell 2010;17:225-234. 3. Pope *et al.* J Neurooncol 2012;107:197-205. 4. Andronesi *et al.* Sci Transl Med 2012;4:116ra114. 5. Choi *et al.* Nat Med 2012;18:624-629. This study was supported by NIH CA159128 and CA154843, and CPRIT RP101243.