

## CAIPIRINHA-DIXON-TWIST (CDT) – Volume-Interpolated Breathhold Exam (VIBE) – A new technique for fast time-resolved dynamic three-dimensional imaging of the abdomen with high spatial resolution

Henrik J Michaely<sup>1</sup>, Katrin Koziel<sup>2</sup>, Philipp Riffel<sup>2</sup>, Johannes Budjan<sup>1</sup>, Stefan O Schoenberg<sup>2</sup>, and Ulrike I Attenberger<sup>2</sup>  
<sup>1</sup>IKRN, UMM, Mannheim, BW, Germany, <sup>2</sup>UMM, Mannheim, BW, Germany

**Target audience:** Clinicians specializing in body imaging

**Purpose:** To assess the feasibility and image quality of a novel highly accelerated T1w-method for time-resolved imaging of the abdomen during first pass of the contrast media transit using CAIPIRINHA (1,2) (controlled aliasing in parallel imaging results in higher acceleration) undersampling, view-sharing techniques and Dixon water-fat separation (CDT-VIBE).

**Methods:** In this retrospective IRB-approved comparison study, 47 patients (median age 62 years, 25M/22F) on a 48-channel 3.0T MR system (Skyra VD 13, Siemens) were included. The CDT-VIBE (TR/TE1/TE2 - 4.1/1.33/2.56ms, acquisition time 29s, CAIPIRINHA acceleration factor 4) was used to replace the arterial phase acquisition and was started 15s after the injection of 0.1mmol/kg Gd-DOTA (Dotarem, Guerbet). Within 29s 14 3D-datasets were acquired and reconstructed using view-sharing (temporal resolution 2.1s) with a high spatial resolution of 1.2x1.2x3mm<sup>3</sup>. The CDT-VIBE images were evaluated by two blinded and experienced radiologists independently with regards to the image quality and the number of hepatic arterial dominant (HAD) phases on an ordinal 5-point scale (5 – excellent, 1 – non diagnostic). If there was an added value to the CDT-VIBE compared to the venous phase abdominal VIBE a note was made. SNR measurements were performed in a separate phantom study with a NiSO<sub>4</sub>-solution to compare the CDT-VIBE with a conventional Dixon-VIBE with CAIPIRINHA acceleration. Both sequences were measured 20 times and the SNR was determined as described by Reeder et al (3).

**Results:** In all patients the CDT-VIBE measurements were successfully acquired as exemplarily shown in Figure 1. The image quality was diagnostic in 46/47 patients. Both readers assessed the best image quality with a median score of 4 (k-statistics 0.789) and the worst image quality with a median score of 3 (k-statistics 0.689). In all but one patient the sequence allowed to visualize the gradual filling of the hepatic arteries and a gradual enhancement of the upper abdominal organs. The image quality was best on the initial frames and tended to decrease towards the end of the measurement. Impaired image quality was most frequently due to failure to hold the breath throughout the entire measurement resulting in coarse artifacts. The continuous motion of the stomach, the intestines and the heart introduced additional slight motion artifacts that were the most common reason for image quality degradation. The number of HAD-frames ranged between 1 and 8 with a median of 5. Added diagnostic value was present in 10/47 patients (21%). Added value included e.g. metastases only seen in the CDT VIBE. In the phantom measurements no significant differences were found between the CAIPIRINHA VIBE (645.0 ± 131.3) and the CDT VIBE (676.3 ± 132.8). A parametric color-coded SNR map is presented in Figure 2.

**Discussion:** CDT-VIBE is a robust approach that for the first time allows dynamic imaging of the upper abdomen with high temporal resolution and maintained high spatial resolution and SNR. It allows a reproducible depiction of the HAD-frame.

**Conclusion:** This new dynamic imaging approach allows robust acquisition of hepatic artery dominant phase in all patients with simultaneous visualization of angiographic data and tumor vascularization.

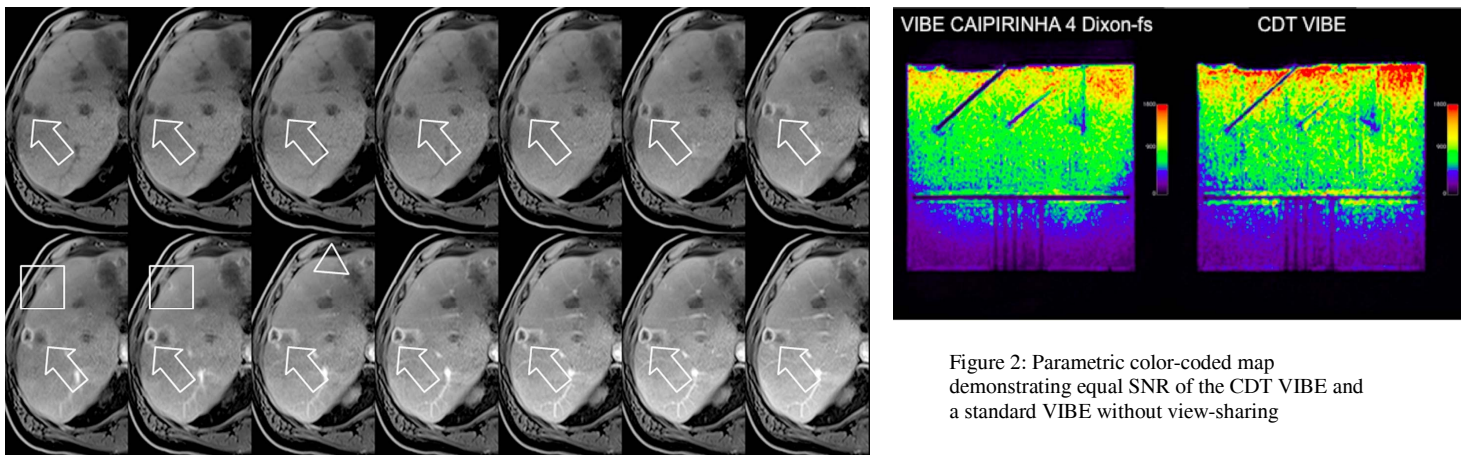


Figure 1: Display of the each of the 14 dynamic frames acquired in a single breathhold in a 73 year-old male patient who had undergone selective internal radiotherapy for colorectal cancer before. The liver demonstrates large avascular metastases (arrowhead) in the left lobe of the liver but also a vividly enhancing subcapsular metastasis in segment 8 (arrow) which shows gradually increasing enhancement throughout the total acquisition. A second only faintly enhancing metastasis can be appreciated anteriorly to the metastasis in segment 8 (box). Please also note the gradual filling of the distal portal vein branches.

**References:**1: Breuer FA et al, MRM 2006, 2:Breuer FA et al MRM 2005, 3: Reeder S et al MRM 2005