

Disrupted Frontal White Matter Development and Integrity in Patients Treated for Pediatric Infratentorial Brain Tumors

John O. Glass¹, Robert J. Ogg¹, Yimei Li², Amar Gajjar³, and Wilburn E. Reddick¹

¹Radiological Sciences, St. Jude Children's Research Hospital, Memphis, TN, United States, ²Biostatistics, St. Jude Children's Research Hospital, Memphis, TN, United States, ³Oncology, St. Jude Children's Research Hospital, Memphis, TN, United States

PURPOSE: Survivors of pediatric brain tumors are at risk for neurocognitive decline [1], and these declines have been attributed to abnormal development of white matter in these patients [2, 3]. The purpose of this study is to compare the white matter development of patients during treatment with cranial radiation and high dose chemotherapy for pediatric medulloblastoma/PNET, atypical rhabdoid tumor, or pineoblastoma to normal healthy age-similar controls.

PATIENTS AND METHODS: The study included 103 patients, ranging in age from 3.2 to 23.5 years at examination (median=10.5 years), treated for infratentorial brain tumors with post-surgical risk-adapted craniospinal irradiation (CSI) plus boost to the local tumor bed and high-dose chemotherapy. Patients received seven magnetic resonance imaging studies: at baseline, after CSI, and 12, 18, 24, 30, and 36 months post-diagnosis. In addition to the patients, 56 normal healthy controls were included, which range in age from 6.0 to 25.7 years at examination (median=13.3 years). Controls were imaged three times: at baseline and 12 and 24 months.

MR imaging was performed on a 1.5T whole-body system (Siemens Medical Systems, Iselin, NJ). Conventional T1, T2, Proton Density and FLAIR imaging was collected on all subjects. These images were registered both within each examination as well as to the baseline study of each subject before being segmented into CSF, gray and white matter (WM) [4]. Diffusion tensor imaging was acquired with twelve non-collinear, non-coplanar diffusion gradient directions and voxel-wise tensor calculations were performed with the DTI toolkit under SPM8 (<http://www.fil.ion.ucl.ac.uk/spm/>) to generate maps of fractional anisotropy (FA). Seven slices were analyzed, four slices above and two slices below an index slice containing the genu, splenium, and basal ganglia. This coverage was further divided into four anatomic regions: left and right frontal and posterior regions. Normal development of the white matter was assessed using a generalized estimating equation method to model the longitudinal data of each subject. Estimates were computed for intercept, change with age, and interaction between age and subject group (patient vs. control).

Table 1. Model parameters from generalized estimating equation method to analyze normal development in patients and controls.

White Matter	Intercept	Age	Age*Group
Right Frontal	30.4 **	0.291 **	-0.203 **
Left Frontal	29.2 **	0.309 **	-0.106 *
Right Posterior	42.6 **	0.502 **	0.004
Left Posterior	42.6 **	0.537 **	0.081
FA	Intercept	Age	Age*Group
Right Frontal	0.373 **	0.004 **	-0.003 **
Left Frontal	0.375 **	0.004 **	-0.003 **
Right Posterior	0.378 **	0.005 **	-0.002 **
Left Posterior	0.375 **	0.006 **	-0.004 **

** $P < 0.01$; * $P < 0.05$

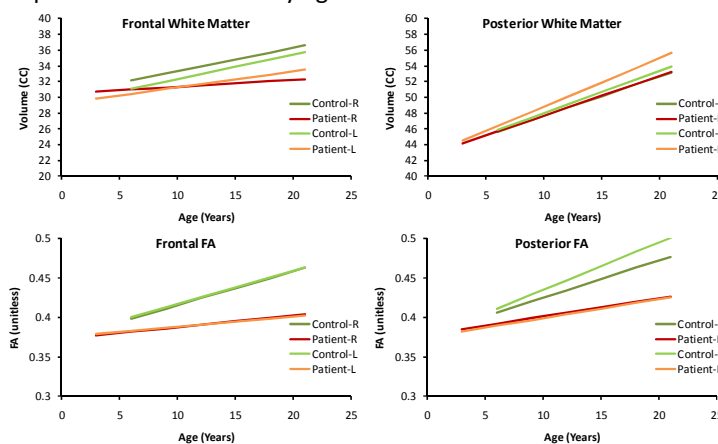
RESULTS: There were a total of 616 patient examinations completed and 166 examinations for the controls. Results of the model parameters are shown in **Table 1**. Statistically significant relationships between age and WM volume and FA are seen in all regions. Additionally, statistically significant differences in these relationships with age were detected between groups for frontal WM volume, and FA in all regions. Data from the model is plotted for these regions in **Figure 1** for easier visualization.

CONCLUSIONS: Frontal white matter in children treated for cancer is hypothesized to be more susceptible to injury due to incomplete myelination. We demonstrate both global volume changes due to therapy in frontal regions as well as structural integrity changes measure by FA throughout the entire brain. Typical maturation of frontal lobe myelination is disrupted in patients treated for pediatric infratentorial brain tumors.

REFERENCE:

- [1] Palmer SL et al. *Eur.J.Oncol.Nurs.* 2009;13:171-8.
 [3] Palmer SL et al. *Brain Imaging Behav.* 2010;4:132-40.

Figure 1. Longitudinal modeling of white matter volume and integrity showing altered developmental trajectories for brain tumor survivors compared to normal healthy age-similar controls.



- [2] Palmer SL et al. *Neuro.Oncol.* 2012;14:1185-93.
 [4] Glass JO et al. *Magn Reson Med* 2004;52:1336-41.