

Integrated PET/MRI with ⁶⁸Ga-DOTATOC in patients with neuroendocrine tumors - first results.

Karsten Beiderwellen¹, Thorsten D. Poeppel², Verena Hartung-Knemeyer², Christian Buchbender³, Hilmar Kuehl¹, Andreas Bockisch², and Thomas C. Lauenstein¹
¹Department of Diagnostic and Interventional Radiology and Neuroradiology, University Hospital Essen, Essen, Germany, ²Clinic for Nuclear Medicine, University Hospital Essen, Essen, Germany, ³Department of Diagnostic and Interventional Radiology, University Hospital Dusseldorf, Dusseldorf, Germany

Target audience

The presentation is addressed to physicians and physicists with special interest in oncologic molecular imaging.

Purpose

Neuroendocrine tumors (NETs) are a rare tumor entity with early liver and bone metastases. The current goldstandard in diagnostic imaging consists of PET/CT with somatostatin-analogues such as ⁶⁸Ga-DOTATOC (DOTA-D-Phe1-Tyr3-octreotide). Due to the superb soft tissue contrast of MRI and the tendency towards early liver metastases, promising results on retrospective PET-MRI-fusion have been suggested for NETs¹. Since this method is time consuming and often defective, it is rarely performed in clinical routine. The first integrated PET/MRI-scanners, that allow for a simultaneous acquisition of PET and MRI, have recently been put into operation. The aim of this pilot study was to demonstrate the potential of simultaneously acquired ⁶⁸Ga-DOTATOC PET/MRI in comparison to ⁶⁸Ga-DOTATOC PET/CT in patients with known gastroenteropancreatic neuroendocrine tumors.

Methods

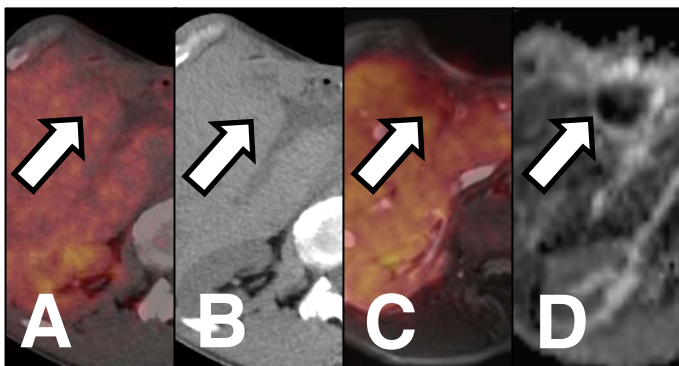
26 patients (12 women, 14 men; aged 53±15 years) with histopathologically confirmed NET underwent a triple phase contrast enhanced PET/CT with ⁶⁸Ga-DOTATOC (Biograph mCT 128, Siemens, Erlangen, Germany). All patients subsequently underwent a whole-body PET/MRI (Biograph mMR, Siemens, Erlangen, Germany). The PET/MRI protocol comprised the following sequences: 1) T1w FLASH, 2) T2w HASTE, 3) DWI, 4) triple phase gadolinium enhanced T1w 3D VIBE of the liver 5) gadolinium enhanced T1w 2D FLASH fs. Two patients were examined without i.v.-contrast due to chronic renal failure. All datasets were rated separately by two radiologists. The criteria comprised lesion count, lesion localization and characterization (benign, indeterminate, malignant). A maximum of 5 lesions per organ were described. All available data (PET/CT, PET/MRI, histopathology) and a clinical follow-up (mean: 110 days) served as standard of reference. Additionally, a case-based descriptive data analysis of PET/CT, PET/MRI was performed. Interobserver variability (Cohens k) were calculated for the ratings of PET/CT and PET/MRI.

Results

According to the reference standard, 15 of 26 patients exhibited malignant NET-lesions. PET/CT allowed for the correct identification of 13 disease-positive patients while all 15 patientes were correctly identified based on PET/MRI. All lesions classified as malignant based on PET/CT (82 lesions) could equally be visualized in PET/MRI. 12 additional liver metastases could be detected based on PET/MRI. One PET-negative liver lesion rated as "intederminate" in a PET/CT without i.v.-contrast could be identified as metastasis in PET/MRI due to a diffusion restriction. 5 PET-negative pulmonary lesions rated as "benign" in PET/CT could not be visualized in PET/MRI. Pulmonary metastases were not present in any of the 26 patients. Interobserver variability was good, equally in PET/CT (k = 0.92) and PET/MRI (k = 0.94).

Discussion

A dedicated whole-body contrast enhanced PET/MRI protocol provides an accurate delineation of NET metastases. Due to the high soft tissue contrast in MRI, lesions not diagnosed in PET/CT can be identified in PET/MRI. This is particularly true if the patient suffers from chronic renal insufficiency and i.v.-contrast is not applicable. Several small, PET-negative pulmonary lesions considered benign in PET/CT were not sufficiently visualized in PET/MRI. However, none of the study patients had pulmonary metastases. Hence, there is only little clinical impact of the drawback of PET/MRI.



PET/CT (A+B) and PET/MRI(C+D) in a patient with PET-negative liver metastasis. Due to renal failure no i.v.-contrast was applied. In pre-contrast CT-scan a hypodense liver lesion could be seen (B, arrow). DWI (D: ADC-map) reveals diffusion restriction in this lesion as sign of malignancy.

Conclusion

Simultaneously acquired PET/MRI with ⁶⁸Ga-DOTATOC shows great potential in whole-body staging of NETs, especially in the detection of NET liver metastases. The value of PET/MRI in lung metastases remains subject for further studies.

References

1. Schreiter NF, Nogami M, Steffen I, et al. Evaluation of the potential of PET-MRI fusion for detection of liver metastases in patients with neuroendocrine tumours. *Eur Radiol.* 2012;22(2):458-467.