

Assessing intracranial vascular compliance using dynamic arterial spin labeling

Lirong Yan¹, Robert Smith¹, Collin Liu², Emily Kilroy¹, Yufen Chen³, and Danny JJ Wang¹

¹Neurology, UCLA, Los Angeles, CA, United States, ²Neurology, USC, Los Angeles, CA, United States, ³Radiology, Northwestern University, Chicago, IL, United States

Target audience: Both clinical and basic scientists in the MRI field

Introduction: A reduction in vascular compliance (VC) is a risk factor/marker of a number of diseases with high social and economical impacts, such as atherosclerosis, hypertension, and diabetes. Aging is also accompanied by a decrease of VC. Currently, VC can be indirectly estimated by measuring aortic pulse wave velocity (PWV)^{1,2} with ultrasound imaging and MRI. To date, however, no method is available for assessing intracranial VC. Spencer and Denison³ defined vascular compliance by the change in arterial blood volume (ΔBV) due to a given change in arterial blood pressure (ΔBP), i.e., $VC = \Delta BV / \Delta BP$. Recently, a new technique for in-vivo estimation of arterial cerebral blood volume (CBV) has been introduced by combining arterial spins labeling (ASL) with a cine segmented multi-phase TrueFISP sequence⁴. By synchronizing ASL with the systolic and diastolic phases of the cardiac cycle, this technique can estimate changes in arterial CBV in response to changes in arterial pressure (i.e., VC). In addition, variations in capillary and tissue perfusion across cardiac cycles can be monitored using Look-Locker based ASL with flow spoiling gradients.

Methods: All experiments were performed on a Siemens Tim Trio 3T scanner. 7 young healthy volunteers (21±2yrs, 5M) and 3 elderly participants (66±2yrs, 3F) participated in this study after providing written informed consents. Blood flow velocities in internal carotid arteries (ICA) were measured using an ECG-triggered time-resolved phase contrast (PC) MRI with the following parameters: FOV= 200×220mm², matrix=192×192, FA=15°, TE=5.23ms, VENC=100cm/s, 13 phases with an interval of 50ms, a single axial slice of 5-mm thickness at the level of C1/C2. The mean flow velocity in ICA across a cardiac cycle is shown in Figure 1. The time delays at peak systole and early diastole were identified in each individual subject (on average 150ms and 400ms following the trigger, respectively). Two ECG-triggered multi-phase TrueFISP ASL scans were performed with pulsed spin labeling applied at the peak systolic and early diastolic phases, respectively, as shown in Figure 1. Imaging parameters were: FOV=220×220mm², matrix=96×96, FA=40°, TE/TR=1.87/3.74ms, 29 phases from 150 to 2250ms with an interval of 75ms. A single slice of 5-mm thickness at the level of M1 was imaged within a scan time of 3min. Arterial CBV maps were calculated based on Eq. [4] of Ref (4). Two ROIs were defined i.e., big arteries with CBV>5%, small arteries and arterioles with CBV of 1.5-5%. Dynamic time courses of the labeled blood signal were derived from the two ROIs of each subject. In addition, capillary and tissue perfusion was imaged using 2 ECG-triggered Look-Locker (LL) EPI ASL⁵ scans with flow spoiling gradients (Venc= 8mm/s, b=9.3s/mm²) at peak systole and early diastole respectively. Imaging parameters were: FOV=220×220mm², matrix size=64×64, FA=25°, TE=35ms, TI=330 to 3330ms with an interval of 300ms. Before and after MRI scans, brachial blood pressure (BP) was recorded using a MR compatible cuff sphygmomanometer.

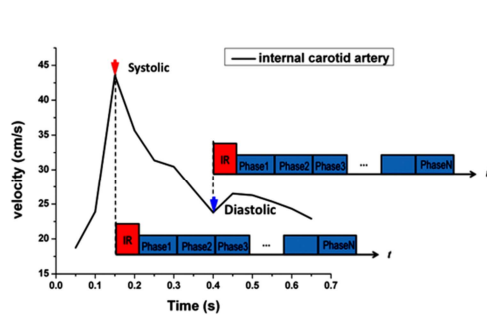


Figure 1. Mean flow velocity curve of ICA with PC MRI. The peak systolic (red arrow) and early diastolic (blue arrow) phases were identified and used to trigger both multi-phase TrueFISP and Look-Locker EPI ASL scans.

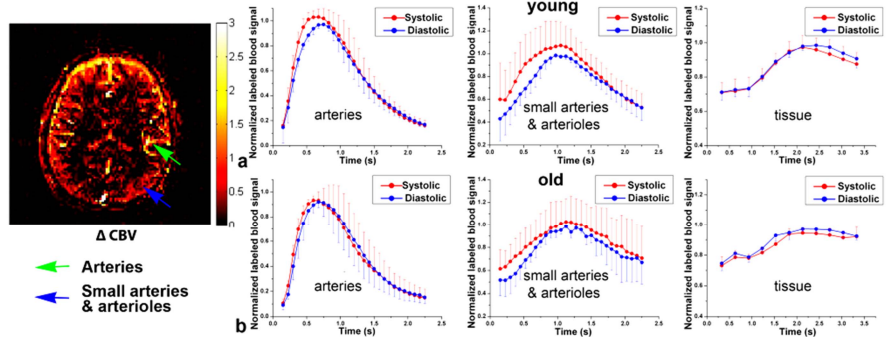


Figure 2. Mean time courses of multi-phase TrueFISP and LL-EPI ASL signals from young(a) and elderly(b) subjects with spin tagging applied at the peak systolic (red) and early diastolic (blue) phases in big arteries, small arteries/arterioles, and capillary/tissue respectively. Error bars indicate standard deviation (SD). A representative map of CBV changes between systole and diastole was shown on the left side.

Results: Figure 2 shows the mean time courses of multi-phase TrueFISP and LL-EPI ASL signals with spin tagging applied at the peak systolic and early diastolic phases in big arteries (>5%), small arteries/arterioles (1.5-5%), and capillary/tissue, respectively. The mean time courses of dynamic ASL signals were normalized by the corresponding peak value of the diastolic curve. As shown in Figure 2a, in the young subjects, elevated labeled blood signals can be observed for the peak systolic time courses in big arteries as well as in small arteries and arterioles, compared to those of the early diastolic phase. The difference between systolic and diastolic time courses, however, is diminished in elderly subjects (see Figure 2b). There was no significant difference between dynamic capillary/tissue perfusion signals between systolic and diastolic phases in both young and elderly subjects. A map of CBV changes between systole and diastole is shown on the left side of Figure 2 from a representative young subject. CBV increases can be observed mainly in arteries, and to a lesser extent in small arteries and arterioles. Under the assumption of an average whole brain volume of 1300mL (can be accurately measured on structural MRI), absolute arterial CBV values were obtained in big arteries and small arteries/arterioles. VC was calculated by ΔCBV divided by ΔBP ($\Delta BP = SBP - DBP$). Figure 3 shows the mean ΔCBV , BP, and VC from young and elderly subjects, respectively. A decrease of CBV change between systolic and diastolic phases were observed in both big arteries and small arteries/arterioles of aged subjects, resulting in a decrease of VC in aged subjects (0.15 ± 0.03 and 0.06 ± 0.02 mL/mmHg for the young subjects, 0.03 ± 0.04 and 0.03 ± 0.02 for the elderly subjects in big arteries and small arteries/arterioles, respectively).

Discussion and conclusion: Using dynamic ASL with multi-phase TrueFISP readout, we demonstrated arterial CBV expansion to comply with arterial pressure differences between the peak systolic vs. early diastolic phases. Vascular compliance mainly occurs in big arteries, gradually decreases in small arteries and arterioles, and finally disappears in capillary and tissue. As a result, capillary and tissue perfusion is stable across cardiac cycles as a potential mechanism to protect capillary endothelium and the blood-brain barrier. A decreased VC with aging was observed, which may result from vascular stiffness with the loss of elastin content and replacement by collagen. While currently brachial BP is applied as the surrogate of intracranial arterial BP, our method does not require the use of external agents (e.g., CO₂, ACZ) to assess cerebrovascular reactivity. The clinical value of our method in vascular disorders awaits evaluation in further studies.

References: [1] Noon JP, Progress in Cardiovascular Nursing, 2009; 24(2):53-8. [2] Langham MC, et al., MRM 2011; 65:750-5 [3] Spencer MP and Denison AB Jr., Am. Physiol. Soc., 1963, vol. II, chapt. 25, p. 842. [4] Yan L, et al., MRM 2012;68(1):130-9. [5] Chen Y, et al., MAGMA2012; 25(2):135-44.

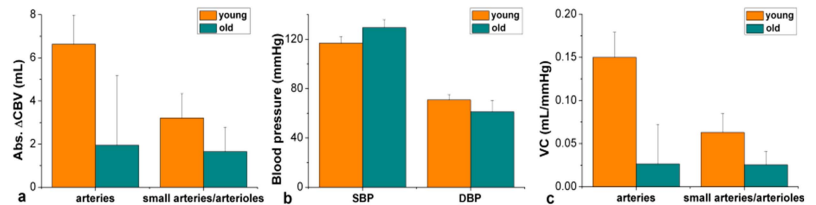


Figure 3. Comparison of absolute CBV changes (a), Systolic (SBP) and diastolic (DBP) blood pressure (b), and vascular compliance (c) between young and elderly subjects.