

Regional Cortical Thickness in Relapsing Remitting Multiple Sclerosis: A Multi-Center Study

Ponnada A Narayana¹, Koushik Govindarajan¹, Priya Goel¹, Sushmita Datta¹, John A Lincoln², Stacy S Cofield³, Gary R Cutter³, Fred D Lublin⁴, and Jerry S Wolinsky²
¹Diagnostic and Interventional Imaging, University of Texas Hlth Sci Cntr Houston, Houston, Texas, United States, ²Neurology, University of Texas Hlth Sci Cntr Houston, Houston, Texas, United States, ³Department of Biostatistics, University of Alabama at Birmingham, Birmingham, Alabama, United States, ⁴The Corinne Goldsmith Dickinson Center for Multiple Sclerosis, Mount Sinai School of Medicine, New York, New York, United States

Introduction:

Regional and global cortical pathology is attracting increased attention in multiple sclerosis (MS). It is generally believed that cortical thinning reflects cortical pathology and could serve as an objective biomarker of the disease. Published literature on cortical thickness in MS is not always consistent because most results are based on relatively small sample size and the age- and gender-dependence are ignored. Motivated by these shortcomings and inconsistencies, we investigated changes in regional and global cortical thickness in MS and the age- and gender dependence of these measures on a large MS cohort that is a part of a multi-center clinical trial.

Methods:

Two hundred and fifty relapsing remitting MS patients who participated in a multi-center clinical trial (188 females, 62 males; age 38.2 ± 9 yrs, range 18-61 yrs; median extended disability status scale (EDSS) of 2, range 0 – 5) and 125 age and gender-matched controls (92 females, 33 males; age 37.3 ± 10.8 yrs, range 20-59 yrs) were included. The MRI data on MS patients were acquired using a rigorous protocol that included 3D T1-weighted images, dual echo FSE, and pre- and post-contrast T1-weighted images. Images were acquired on different scanners operating at different field strengths. A pipeline was developed for automatically identifying images with suboptimal quality (ghosting, aliasing, poor SNR, etc.). Control data was accessed from publicly available databases. Freesurfer pipeline was used for global and regional cortical thicknesses measurements (1). A multiple comparison Monte-Carlo simulation with 5000 iterations was performed to make inferences at $p = 0.001$ at a false discovery rate of (FDR), $p < 0.05$.

Results:

Figure 1 shows regional cortical thinning in the left hemisphere on an inflated brain in MS patients compared to age and gender matched controls. In these figures, different colors denote multiple cortical regions with significant cortical thinning in the MS cohort relative to the controls. Overall, cortical thinning was more prominent in the left hemisphere relative to the right hemisphere. The average cortical thickness in healthy controls demonstrated relatively strong negative correlation with age ($R = -0.50$; $p = 3.84e^{-9}$). In contrast, the average cortical thickness in MS patients showed only weak age dependence ($R = -0.19$; $p = 0.003$) (Fig. 2). Cortical thickness in MS patients was smaller than in normal controls at the corresponding age. In general, various regional structures showed stronger age dependence in healthy controls compared to MS patients. Male subjects showed stronger age dependent cortical thickness than females.

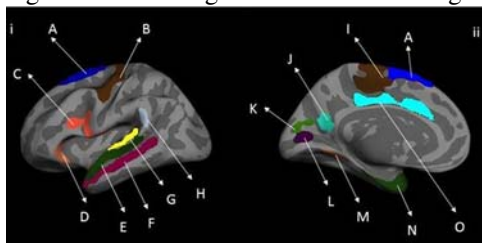


Figure 1. Lateral (i) and medial (ii) views of inflated left hemisphere group difference maps
The highlighted regions are: (A) superior frontal, (B) precentral, (C) pars opercularis, (D) pars orbitalis, (E) superior temporal, (F) middle temporal, (G) transverse temporal and portions of the superior temporal gyrus, (H) supramarginal, (I) paracentral, (J) precuneus, (K) cuneus, (L) pericalcarine, (M) fusiform, (N) entorhinal and portions of temporal pole, and (O) cingulate.

Discussion and Conclusions:

In this cross sectional, multi-center study, a comprehensive analysis of global and regional cortical thickness was performed on a large RRMS cohort with relatively low clinical disability. Poor image quality affects the measured cortical thickness. Therefore, the QA protocol implemented in these studies for automatically identifying images with poor quality is critical since in multi-center studies it is almost impossible to examine each image. Our studies show that left hemisphere, considered to be the

dominant hemisphere, is more affected than the right. We observed the strongest reduction in cortical thickness in the entorhinal cortex and temporal poles in MS, the structures implicated in several neurodegenerative diseases. We observed weaker age dependent changes in both global and regional cortical thicknesses in MS patients compared to controls. This is different from a previous report in which strong age-dependent changes were reported in MS (2). Our results of bilateral thinning of frontal and temporal association areas in RRMS are consistent with published

reports (3). We demonstrated significant cortical thinning in our cohort with low clinical disability, though, the reductions in cortical thickness in precentral and frontal areas were smaller than the published reports (4).

References:

- 1) <http://surfer.nmr.mgh.harvard.edu/fswiki> 2) Sailer M et al Brain 2003;126:1734 3) Calabrese M Neurology 2010;74:321 4) Charil A et al . Neuroimage. 2007;34:509

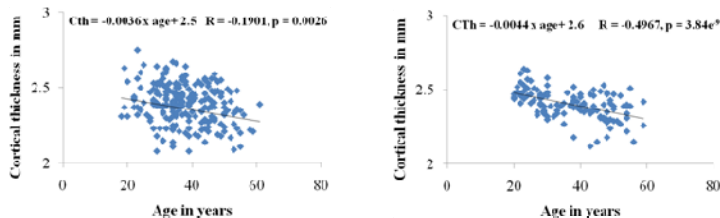


Figure 2. Regression plots of average cortical thickness vs. age in MS subjects (left) and controls (right)