

ESTIMATION OF PLACENTA FUNCTION USING T_2^* MEASUREMENTS DURING HYPER- AND NORMOXIA

David Alberg Peters¹, Anne Sørensen², Ernst-Torben Wilhelm Fründ³, Ole Bjarne Christiansen², and Niels Uldbjerg⁴

¹Department of Clinical Engineering, Central Denmark Region, Aarhus N, Denmark, ²Department of Gynecology and Obstetrics, Aarhus University, Aalborg Hospital, Aalborg, Denmark, ³Department of Radiology, Aarhus University, Aalborg Hospital, Aalborg, Denmark, ⁴Department of Gynecology and Obstetrics, Aarhus University Hospital, Skejby, Aarhus N, Denmark

Introduction

MR imaging is becoming widely used for pre natal diagnosis¹. Conventional pre natal imaging focuses on structural changes, but recently several groups have begun to investigate changes in the MR signal during oxygen breathing. The main focus has been changes in the BOLD signal^{2,3} in organs such as liver, brain, lungs and heart. In this study we investigate the feasibility of pre- and post-oxygen T_2^* measurements to evaluate the function of the placenta.

Methods

Six healthy pregnant women (gestational week 28-35) were examined in a GE 450W magnetic resonance scanner (GE Healthcare, Milwaukee, WI). The MR examination was performed as follows: Following initial planning and reference scans a gradient echo sequence with multiple readouts was performed: TR=70.9 ms, TE=3.02 to 67.5 ms in steps of 4.3 ms, FOV 350x350 mm, Matrix 256x128 resulting in an inplane resolution of 1.37x2.73mm, and three slices of eight mm in thickness. Following the initial multi echo acquisition, the mother was supplied with oxygen through a mask. After 5 minutes of oxygen breathing a second multi echo MR scan was performed with identical settings to the pre-oxygen scan, while the mother was wearing the oxygen mask.

A large region of interest (ROI) was drawn in the placenta by a trained obstetrician for each scan. In case of severe fetal motions the ROI was either moved or the given echo time discarded. The average signal from each ROI as a function of echo time was plotted and a monoexponentially decaying function with M_0 and T_2^* as free parameters was fitted using a Levenberg-Marquardt least squares fitting function (figure 1). Pre- and post-oxygen T_2^* values were compared using a Students t-test. A 95% significance level was used.

Results and discussion

T_2^* in the placenta increased for all subject from pre- to post-oxygen (figure 2). The pre oxygen T_2^* values displayed a large variability between the measured subjects, which could be caused by differences in homogeneity of the shim for each subject. The mean T_2^* value for all subjects increased significantly between pre- and post-oxygen scans, from 71 ± 10.8 ms to 99.5 ± 18.4 ms ($P=0.009$).

Figure 3 shows a map of T_2^* values within the ROI averaged in figure 1. It is clear that there is spacial heterogeneity in the pre-oxygen map compared to the post-oxygen map which is more homogenous. The areas with low T_2^* (blue) (figure 3, top) could represent the fetal side of the placenta which has an inherently lower oxygenation⁴ than the maternal side and hence a higher fraction of deoxyhemoglobin which is paramagnetic and lowers T_2^* .

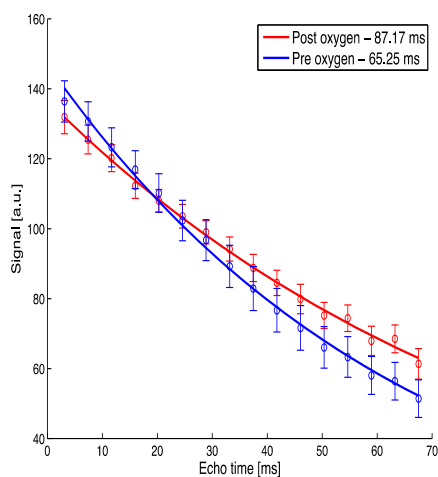


Figure 1: Signal as a function of TE for a subject before (blue) and after (red) oxygen. Bars are S.E.M.

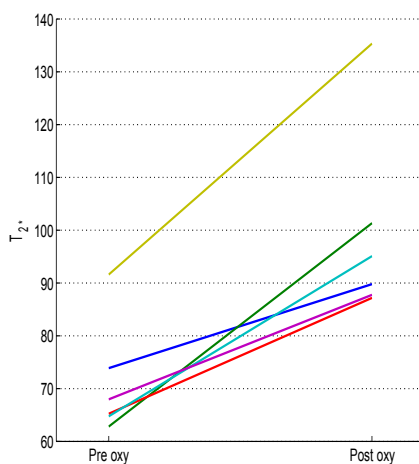


Figure 2: Fitted T_2^* values for the six subjects before and after oxygen.

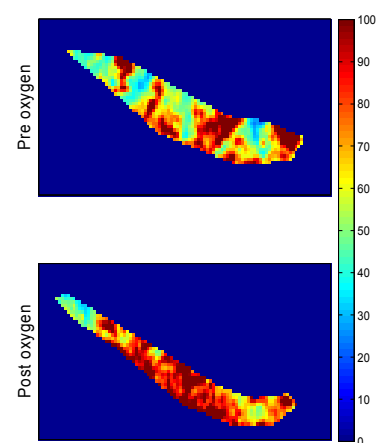


Figure 3: T_2^* map of placenta before (top) and after (bottom) oxygen, Same subject as in figure 1.

Previous attempts at demonstrating differences in T_2^* pre and post oxygen in the fetal liver have not been successful⁵. The reason that we are able to demonstrate a change in T_2^* in the placenta could be caused by a higher blood volume in placenta or that the number of acquired echoes was high (16) which could lead to more precise T_2^* estimates. Furthermore the proposed method is more reproducible as the pregnant women were not repositioned after applying the oxygen mask.

Conclusion

We have demonstrated that T_2^* in the placenta changes significantly after oxygen breathing. With further development this method could be used to evaluate the function of placenta using a non-invasive method. This could for instance be of great value in determining the optimal time to deliver a growth restricted fetus.

References

- 1) Levine D, JMRI, 2006;24(1):1-15
- 2) Sorensen et al, UOG, 2009;34(6):687-692.
- 3) Wedegärtner et al, Radiology 2006;238(3):872-880.
- 4) Gregg et al, Clin Obstet Gynecol, 1993;36(1):24-32
- 5) Morris et al, Physiol. Meas. 2010;31:1137-1146