

Intra-renal oxygenation by BOLD MRI in Rat Model of Contrast Induced Nephropathy: Evaluation by R2* and R2'

Lu-Ping Li¹, Hongyu An², Tammy Franklin¹, Ujala Bokhary¹, Anindya Sen¹, and Pottumarthi V Prasad¹

¹Radiology Dept., Northshore University Healthsystem, Evanston, IL, United States, ²Radiology, University of North Carolina, Chapel Hill, NC, United States

INTRODUCTION

Blood oxygenation level-dependent (BOLD) MRI is gaining acceptance as a viable method of monitoring intra-renal oxygenation status [Circulation. 1996;94(12): 3271-5; Magn Reson Imaging Clin N Am 16 (2008) 613–25]. R2* is widely used to evaluate renal BOLD effect, primarily due to fast data acquisition and widespread availability. However, it is well known that R2* is inherently dependent on R2 in addition to the susceptibility induced relaxation, R2' which should be directly related to deoxyhemoglobin. While R2' can be estimated by measuring R2* using GRE and R2 by SE, there are sequences based asymmetric spin echo (ASE) that could provide direct mapping for R2' [Magn Reson Med 50:708–716 (2003)]. In this study, preliminary data was acquired with this sequence in rat kidneys before and after administration of iodinated contrast agents in a model of contrast induced nephropathy (CIN) [J Clin Invest. 1994;94(3):1069-75] and compared with R2* measurements by mGRE sequence.

METHODS

The study protocol was approved by our IACUC. Male Sprague-Dawley rats were anesthetized by inactin (100 mg/kg i.p.) and femoral vein was catheterized. Four groups based on the contrast agents were further subdivided into pre-treatment group: receiving nitric oxide synthase inhibitor, N-nitro-L-arginine methyl ester (L-NAME, 10mg/kg) and prostaglandin inhibitor, indomethacin (10 mg/kg) prior to radio-contrast; and control group: receiving two times saline instead. One of the four radio-contrast agents (iodixanol, iohexol, ioxaglate and iothalamate) was administered at 1600 mg organic iodine per kilogram of body weight. Group assignments were made in a random order and blinded fashion.

Imaging was performed on a 3.0 T scanner (Magnetom Verio, Siemens, Germany). R2* images were acquired using a multiple gradient recalled echo sequence (TE=3.6-41.3ms; FOV=12x6cm; TR=69ms; bandwidth=320Hz/pixel; FA=30°; NEX=20; matrix: 256x256; slice thickness=2mm) to acquire 12 T2* weighted images. R2' weighted images were acquired using asymmetric spin echo (ASE) single shot echo planar (EPI) imaging sequence (TE=61ms; FOV=16cm; TR=3s; bandwidth=960Hz/pixel; matrix: 128x128; slice thickness=3mm; average=8) with the 180 refocusing pulse offset by tau while keeping the TE time constant. Twenty images were acquired with varying tau in the range of 20 ms to 40 ms in steps of 1.0 ms [Magn Reson Med 50:708–716 (2003)].

The rat kidneys were positioned in the middle of the standard knee coil. One transverse slice was selected in the middle of the kidney. BOLD MRI data was acquired as shown in the timing diagram (left). R2' images were acquired in 26 (out of 48) rats prior to and at the end of the BOLD MRI sequence of acquisitions. The first and last BOLD MRI data were used to compare R2* vs. R2'. R2* and R2' maps were generated offline using a custom Matlab code. ROIs were chosen on R2* maps in inner-strip of outer medulla (ISOM), outer-strip of outer medulla (OSOM), inner medulla (IM) and cortex (CO). Signal intensity vs. tau data was fit to an exponential function using XLFIT (IDBS Inc., UK) to estimate R2'.

RESULTS

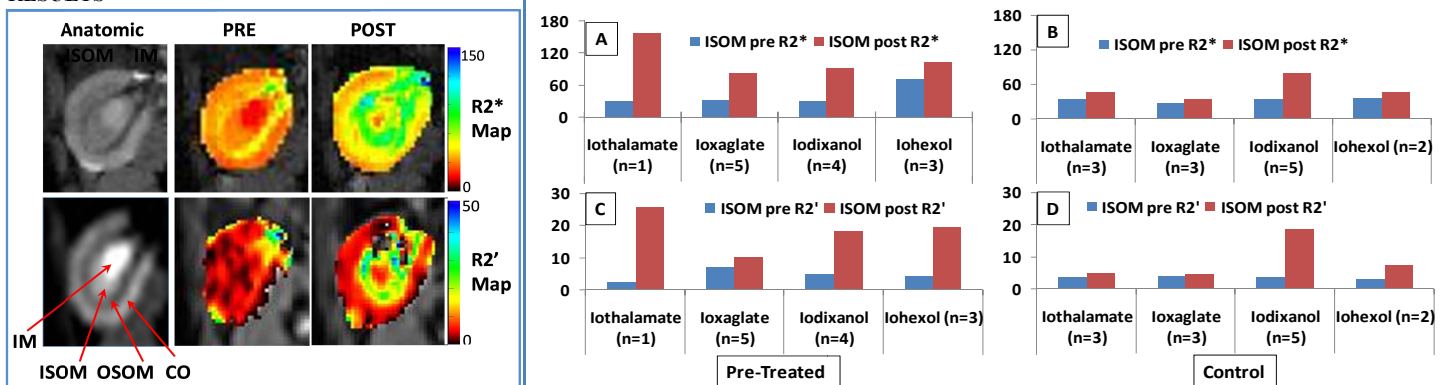


Figure on the left show representative images from one rat. Shown are anatomic image from mGRE scan and R2* maps at baseline and after administration of contrast agent (top). Similarly, anatomic image from ASE-EPI scan along with R2' maps at baseline and post-contrast are also shown (bottom). The windowing for the pre- and post-contrast maps were identical. Only results in ISOM are summarized here, but the results in other renal regions show similar trends. Figure on the right show summary of pre- and post-contrast R2*(A & B) and R2'(C & D) in ISOM with 4 different radio-contrast agents used in pre-treatment groups (A & C) and control groups (B & D). Note that the trends observed in R2* and R2' are similar suggesting that the predominant contribution to changes observed on R2* are due to susceptibility based differences, *i.e.* those related to changes in oxygenation status of hemoglobin.

DISCUSSION AND CONCLUSION

Our preliminary experience supports the feasibility of acquiring R2' maps using ASE-EPI sequence in kidneys to evaluate intra-renal oxygenation. The use of single shot EPI limits the shortest TE and the range of tau values. The range of tau values used in this study was more optimal for post-contrast measurements (T2' ~ 40 ms) than the pre-contrast measurements (T2' ~ 200 ms). Segmented EPI readout may afford more flexibility in terms of range of tau values and choice of TE and minimize the blurring due to signal decay during EPI readout. The same is true for spatial resolution. Alternately, fast spin echo readout could avoid inherent limitations of EPI [Magn Reson Imaging. 2010 Nov;28(9):1270-82].

While the magnitude of baseline R2* and R2' are consistent with a ballpark estimate of R2 ~ 20 s⁻¹ at baseline, the post-contrast measurements show the difference between R2* and R2' is higher than 20 s⁻¹. This is probably due to the use of dephasing gradients to eliminate vascular contributions in the ASE sequence. Future validation should include acquiring all R2*, R2 and R2' maps. Translation to human use may require implementation of respiratory triggering or other free breathing approaches. Alternate multiple breath-hold acquisitions could be combined with some spatial registration techniques.

ACKNOWLEDGEMENTS: Work was supported in part by a grant from the National Institutes of Health, R01- DK-053221.