

FRACTIONAL ANISOTROPY DIFFERENCES IN BASAL GANGLIA IN NEUROLOGICAL AND NEURODEGENERATIVE DISORDERS

Gonzalo Pajares¹, Juan Antonio Hernández-Tamames², Pablo García-Polo³, Norberto Malpica², Ana Ramos⁴, and Juan Álvarez-Linera⁵

¹Fundación CIEN - Fundación Reina Sofía, Madrid, Spain, ²Universidad Rey Juan Carlos, Spain, ³Centro de Tecnología Biomédica, Spain, ⁴Hospital Universitario 12 de Octubre, Spain, ⁵Hospital Ruber Internacional, Spain

Introduction:

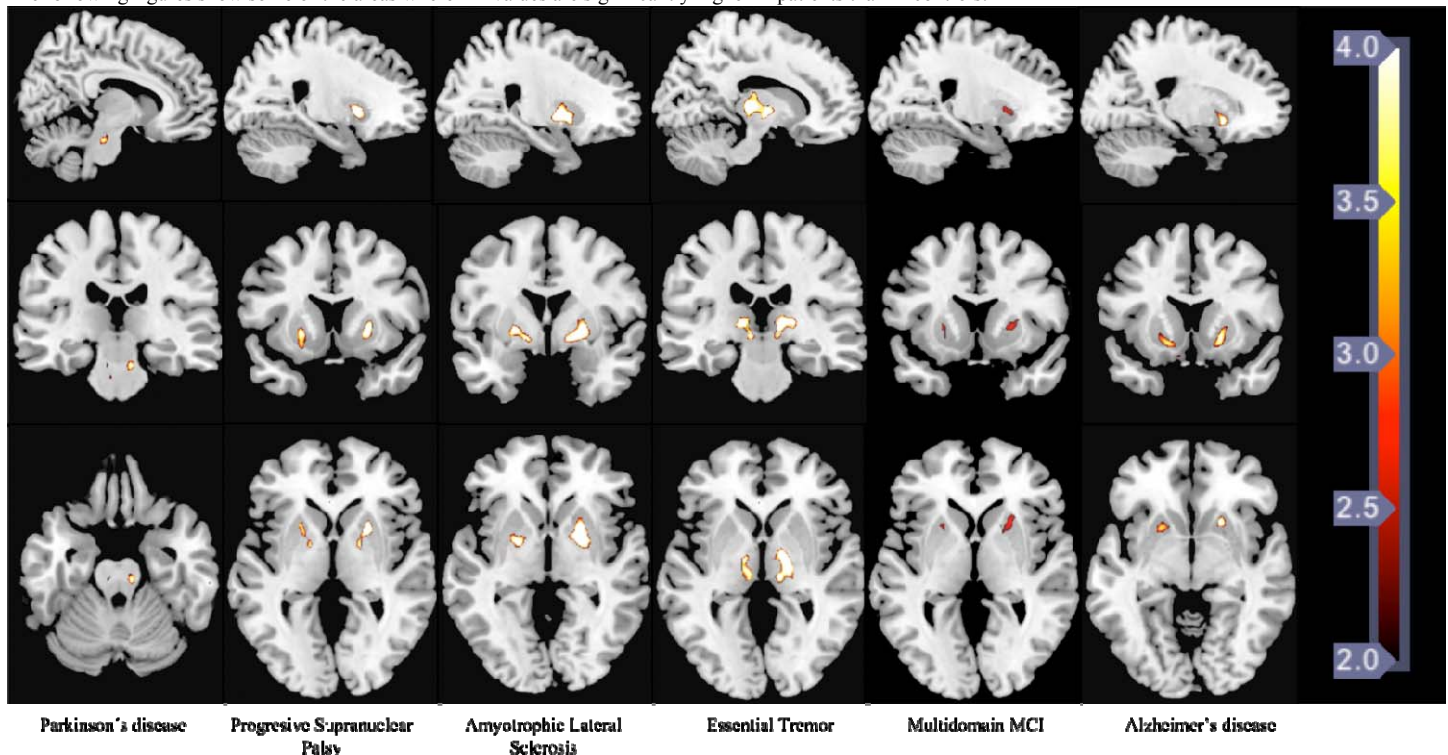
Diffusion Tensor Imaging (DTI) has been typically used to appraise white matter microstructure changes in the brain. Recently this technique is being used to study gray matter structures [1,2]. Although no major differences in fractional anisotropy in gray matter are expected, significant differences appear in basal ganglia when comparing pathological groups with control groups. The aim of this research is to point out the differences in gray matter structures in several diseases.

Material and Methods:

Nineteen patients with Parkinson's disease (PD), thirteen patients with Progressive Supranuclear Palsy (PSP), thirteen patients with Amyotrophic Lateral Sclerosis (ALS), seventeen patients with Essential Tremor (ET), twenty patients with multidomain Mild Cognitive Impairment (m-MCI) and forty-eight patients with Alzheimer's disease (AD) were studied. The control subjects were paired in age and sex with the pathological groups respectively. A Fractional Anisotropy (FA) map of each subject was obtained using Functool software (GE 4.3. Advantage Windows WS), correcting the images for eddy current artifacts. The b=0 images were registered to the T2 template, included in the Statistical Parametric Mapping software. The computed spatial transformation was applied to the FA maps. The b=0 images of the control group were then normalized to the T2 template, applying the same spatial transformation to the FA maps. These normalized FA maps were smoothed with a 4x4x4 mm FWHM Gaussian kernel and averaged, to create a FA template. Finally every initially registered FA map was normalized to the FA template and smoothed with a 4x4x4 mm FWHM Gaussian kernel. Statistical analysis was performed using the SPM software, which applies the General Linear Model to construct t statistics images.

Results:

The following figures show some of the areas where FA values are significantly higher in patients than in controls:



Depending on the pathology, this increase affects different ganglia: the substantia nigra in PD; the pallidus, putamen and substantia nigra in PSP; the putamen, pallidus and frontal cortex in m-MCI and AD; only the thalamus in ET and, finally, the pallidus and putamen in ALS. In the figure above, some of these affected regions are shown.

Conclusions:

The reason for the significant increase in FA values in patients, when compared to controls, is unknown. One of the most plausible hypotheses is the presence of iron deposits in the brain as mentioned in [2]. It is noticeable that iron deposits have been found in PD in substantia nigra [3], in PSP in putamen and substantia nigra [4], and in m-MCI and EA in pallidus and cerebral cortex [5]. In m-MCI, the same areas are affected as in Alzheimer's disease, but with smaller FA values. It could be explained as a different stage in the illness progression. Regarding ALS and ET, as far as we know, there is no literature about abnormal FA values or iron deposits in the affected regions for these pathologies.

Anyway these results point out the need of carrying out more specific studies on these populations in order to figure out the origin of these abnormal FA values. The results in m-MCI and AD could provide an additional staging biomarker for this pathology.

References:

- [1] Pfefferbaum, A. et al. *DTI of Deep Gray Matter Brain Structures: Effects of Age and Iron Concentration*. Neurobiology of Aging 31, 482-493. 2010.
- [2] Awasthi, R. et al. *Diffusion Tensor MR Imaging in Children with Pantothenate Kinase – Associated Neurodegeneration with Brain Iron Accumulation and Their Siblings*. American Journal of Neuroradiology 31, 442-447. 2010.
- [3] Zhang, J. et al. *Characterizing Iron Deposition in Parkinson's Disease Using Susceptibility-Weighted Imaging: an in Vivo MR Study*. Brain Research 1330, 124-130. 2010.
- [4] Drayer, B.P. et al. *Parkinson Plus Syndrome: Diagnosis Using High Field MR Imaging of Brain Iron*. Radiology 159, 493-498. 1986.
- [5] Loeffler, D.A. et al. *Transferrin and Iron in Normal, Alzheimer's Disease, and Parkinson's Disease Brain Regions*. Journal of Neurochemistry 65, 710-716. 1995.