

Methylene Blue (a Metabolic Enhancer) Increases Basal CBF, and Hypercapnic and Functional fMRI Responses

Shiliang Huang¹, Fang Du¹, Yen-Yu I Shih¹, Qiang Shen¹, Ai-Ling Lin¹, Shao-Hua Yang², and Timothy Q Duong¹

¹Research Imaging Institute, University of Texas Health Science Center at San Antonio, San Antonio, TX, United States, ²Department of Pharmacology and Neuroscience, University of North Texas Health Science Center at Fort Worth, Fort Worth, TX, United States

INTRODUCTION Methylene blue (MB) is FDA-approved to treat methemoglobinemia and cyanide poisoning (1). More recently, MB has been shown to have potential neuroprotective effects in a number of neurological diseases, including stroke, Alzheimer and Parkinson diseases (2) in preclinical and clinical studies with minimal side effects. MB can sustain ATP production by acting as an electron donor in the mitochondrial electron transport chain. It also reduces free radical production under metabolically stressed conditions because it by-passes the free radical production in the electron transport chain (2). The effects of MB on hemodynamics and functional activations in the brain in vivo, however, have not been previously explored. The goal of this study is to use MRI to investigate the effects of MB on basal CBF, fMRI responses to hypercapnic challenge and forepaw stimulations, and evoked oxygen consumption changes.

METHODS Male Sprague Dawley rats (N=4, 200-300g) were anesthetized with 0.9~1.0% isoflurane, mechanically ventilated, and paralyzed with pancuronium bromide (3 mg/kg first dose, 1 mg/kg/hr, ip). MRI measurements were made before and after MB (0.5 mg/kg, iv over 5 mins) injection in the same animals. Hypercapnic challenge used 2 mins air, 3 mins 5% CO₂ inhalation followed by 5 mins air. Bilateral forepaw stimulation used 4 epochs (96s OFF and 30s ON) of 2 mA, 8 Hz and 1 ms pulse. MRI studies were performed on a 7T/30cm magnet and a 40G/cm BGA12S gradient insert (Bruker, Billerica, MA). Rats were placed in a head holder consisting of ear and tooth bars. Combined CBF and BOLD measurements were made using the continuous arterial spin-labeling technique with TR = 3 s, TE = 20 ms, matrix = 96x96, and FOV = 25.6x25.6 mm (3). CMRO₂ was calculated using the biophysical model as described elsewhere (4). Analysis included whole-brain and forepaw primary somatosensory cortex ROI. Paired t-test was used with P < 0.05 indicating statistical significance.

RESULTS Hypercapnia and forepaw stimulation evoked statistically significant changes in BOLD, CBF and CMRO₂ both before and after MB injection (P<0.05).

MB increased CBF by 4.3% albeit not significantly (**Figure 1**). MB significantly enhanced hypercapnia-induced BOLD (P=0.015, **Figure 2**) and forepaw-evoked BOLD responses (P=0.019, **Figure 3**). Hypercapnia and forepaw-evoked CBF were also enhanced by 20% and 50%, respectively but did not reach to statistical significance due to small sample size and lower CNR for CBF fMRI. The M values were 6.6±0.5% before MB and 6.8±0.4% after MB (P=0.14). The CMRO₂ changes due to forepaw stimulation were 4.23±0.98% before MB and 7.40±0.96% after MB (P=0.006).

DISCUSSION Basal CBF, hypercapnic and forepaw fMRI responses are consistent with those reported previously in isoflurane-anesthetized rats (4). These results suggest that MB enhances brain functions by way of providing substrates for increased ATP production under metabolically stressed conditions. This could in part explain the observed neuroprotective effect in stroke and improved cognitive function in Alzheimer disease after MB treatment (2,3). The increases in hypercapnic fMRI responses suggest that MB also has hemodynamic, in addition to metabolic, effects. Future studies will measure ATP and lactate production and investigate functional activations under metabolically stressed, hypoxic and ischemic conditions.

In conclusion, MB increases basal CBF, hypercapnia-induced and forepaw-stimulation fMRI responses and oxygen consumption during forepaw stimulation. These results support the positive benefits of MB for treatments. Non-invasive MRI approach may prove useful in future MB studies of disease models and clinical trials.

References (1) Scheindlin, Mol Interv 8:268 (2008). (2) Wen et al. J Bio Chem. 286:16504 (2011). Medina et al., Brain Pathol: 21, 140-149. (3) Shen et al, JCBFM 23:1479 (2003). (4) Liu et al. MRM 52:277 (2003).

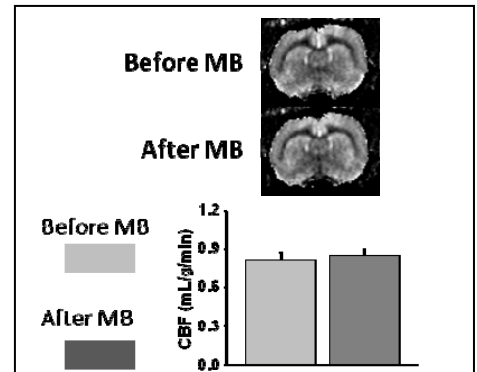


Figure 1. CBF before and after MB injection.

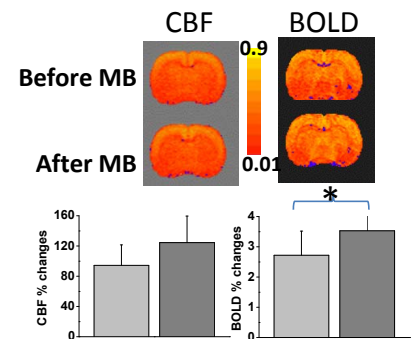


Figure 2. Hypercapnia-induced CBF and BOLD % changes. Color bar = cross correlation coefficient. Error bars = ± SD, N = 4.

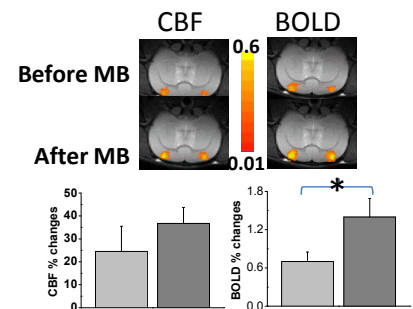


Figure 3. Forepaw-stimulation CBF and BOLD % changes. Color bar = cross correlation coefficient. Error bars = ± SD, N = 4.