

APPLICATION OF ^{13}C METABOLIC IMAGING FOR THE ASSESSMENT OF ISCHEMIA IN THE PERFUSED HEART

Daniel Ball¹, Rachel Cruickshank¹, Carolyn Carr¹, Daniel Stuckey², Kieran Clarke¹, and Damian Tyler¹

¹Physiology, Anatomy and Genetics, Oxford University, Oxford, Oxfordshire, United Kingdom, ²Imperial College, London, United Kingdom

Introduction: Non-invasive cardiac imaging increasingly plays a fundamental role in diagnosing, assessing prognosis, and monitoring therapy response in cardiovascular disease. Magnetic resonance imaging allows for detailed study of cardiac structure, contractility and viability but with the recent advances in the sensitivity of the ^{13}C nucleus via the Dynamic Nuclear Polarization (DNP) process, it is now possible to obtain cardiac metabolic images. Combining DNP with Chemical Shift Imaging (CSI)¹ provides a potential method with which to assess the metabolic changes related to cardiovascular disease and to examine the heterogeneity of any such metabolic alterations. The aim of this work was to demonstrate the use of a DNP-CSI protocol² in the isolated perfused heart to image metabolism in the setting of both acute and chronic myocardial ischemia.

Materials and Methods: To assess the metabolic effects of acute ischemia, hearts from male Wistar rats (n=5) were perfused in the Langendorff mode and, following baseline metabolic assessment, a stitch was tied around the left descending coronary artery to restrict the flow of buffer to the antero-lateral portion of the left ventricle. To assess chronic ischemia, an *in vivo* myocardial infarction model was used³, in which male Wistar rats (n=4) were anaesthetised and a thoracotomy was performed to allow a stitch to be placed around the left descending coronary artery. Four weeks later the hearts were excised for Langendorff perfusion and DNP-CSI performed.

Heart perfusion: Hearts were perfused in the Langendorff mode with Krebs-Henseleit buffer containing 10 mM glucose and 2.5 mM pyruvate and oxygenated with 95% O₂/5% CO₂. The hearts were placed in the bore of an 11.7 T MRI system (Bruker-Biospin, Germany) for spectral assessment.

MR Assessment Protocol: An initial ^{31}P spectrum was acquired to assess the energetic status of the whole heart, followed by a first pass gadolinium contrast protocol⁴ to assess cardiac perfusion. This was followed by a combined hyperpolarized DNP dissolution and CSI protocol, as previously described², which yielded images of the infused pyruvate and its metabolic conversion to lactate and bicarbonate (TR = 0.5 s, FA = 45°, slice thickness = 5 mm, FOV = 24 x 24 mm, Matrix = 8 x 8, Averages = 2). In the acute ischemia experiments, the heart was then removed from the magnet, a stitch placed around the left descending coronary artery, the heart replaced in the centre of the magnet and the entire protocol repeated.

Results and Discussion: The first pass gadolinium contrast acquisition demonstrated that both models of ischemia led to reduced perfusion in the area of myocardium supplied by the left anterior coronary artery (infarct region). In both the acute and chronic models, reduced pyruvate signal was seen in the infarct region, confirming the reduction in perfusion. However, in the acute ischemia model, there was also a significant increase in the relative production of lactate and a concomitant decrease in the relative production of bicarbonate in the infarct region (Figure 1), despite no alteration in cardiac energetics. This would suggest a demonstrable change in metabolism in the acute ischemia model consistent with a reduction in aerobic oxidation and a shift to anaerobic metabolism. In the chronic ischemia model, there was a significant reduction in cardiac energetics (PCr/ATP) when compared to control hearts and a significant reduction in metabolism in the infarcted region which was proportional to the reduction in perfusion.

Conclusion: In this work, a DNP-CSI protocol was successfully applied to identify infarcted areas of the perfused heart in two different models of ischemia. A switch towards anaerobic metabolism was observed in the setting of acute ischemia. Future work will investigate the translation of these techniques to *in vivo* rodent models of ischemia.

References [1] [Golman et al, Magn Reson Med, 2008, 59, 1005-13], [2] [P. Lee et al, ISMRM 2010], [3] [Carr et al, Am J Physiol Heart Circ Physiol. 2008 Aug;295(2):H533-42], [4] [Stuckey et al, J Cardiovasc Magn Reson. 2011 Aug 3;13:38]

Acknowledgements: This study was supported by the Medical Research Council, the British Heart Foundation and Oxford Instruments Molecular Biotoools.

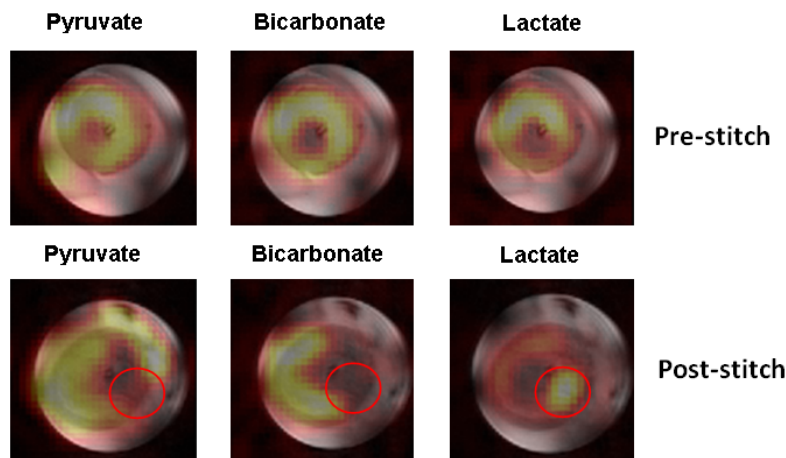


Figure 1: A post-stitch decrease in bicarbonate and increase in lactate signal was observed in the infarct zone in the acute ischemia model