

Magnetic Resonance Imaging Is More Sensitive Than Computed Tomography Angiography for the Detection of Endoleaks After Endovascular Abdominal Aortic Aneurysm Repair: A Systematic Review

Jesse Habets¹, Herman J.A. Zandvoort², Johannes B. Reitsma³, Frans L. Moll², L. Wilbert Bartels⁴, Joost A. van Herwaarden², and Tim Leiner¹

¹Radiology, University Medical Center Utrecht, Utrecht, Netherlands, ²Vascular Surgery, University Medical Center Utrecht, Utrecht, Netherlands, ³Julius Center for Health Sciences and Primary Care, University Medical Center Utrecht, Utrecht, Netherlands, ⁴Image Sciences Institute, University Medical Center Utrecht, Utrecht, Netherlands

Introduction:

Abdominal aortic aneurysms (AAA) are increasingly being treated by exclusion of the aneurysm sac from the circulation with endovascular repair (EVAR). The aims of EVAR are depressurization of the aneurysm sac and arrest of aneurysm growth¹. After EVAR, life-long surveillance is required to detect complications such as endoleaks, stent graft migration and/or kinking. Endoleak is defined as persistent leakage of blood into the aneurysm sac and has been associated with continued aneurysm growth and increased chance of rupture. Endoleaks are classified into different types, each of which have a different treatment strategy². The routine imaging technique for the detection of endoleak is biphasic computed tomography angiography (CTA)³. However, CTA may miss the presence of endoleak⁴. There is increasing evidence that magnetic resonance imaging (MRI) may detect endoleaks more accurately. The purpose of this systematic review was to examine reported differences in endoleak detection rate between MRI and CTA in patients after EVAR.

Material and methods: A systematic electronic search in Pubmed and Embase was performed. Inclusion of articles was performed by two independent reviewers. Articles were included when post-EVAR patients were evaluated by both MRI as index test and CT angiography (CTA) or digital subtraction angiography (DSA) as comparison. No publication date restriction was applied. Language was restricted to English articles. Cross-referencing was performed. Methodological quality of included studies was assessed with the QUADAS tool⁵. Primary outcome was the proportion of patients in whom additional endoleaks were detected by MRI, not seen with comparator modalities. Random effects meta-analysis and meta-regression was performed in dedicated SAS 9.1 statistical software. A Forest plot was generated to depict the proportion of additional endoleaks detected by MRI including 95% confidence intervals (CI).

Results: Thirteen articles were found and included in the systematic review. In total, 421 patients with 613 MRI and CTA/DSA examinations were included. A total of 196 endoleaks were detected by CT or DSA; all except one were also detected by MRI. MRI detected 132 additional endoleaks. To explore possible explanations for this finding three different populations were studied in more detail: (1) studies in patients with known endoleaks on CTA/DSA ($n=3$); (2) studies in unselected patients without knowledge of endoleak existence ($n=10$); and (3) one study in patients without known endoleaks but non-shrinking AAA (fig. 1). In the unselected patient population (2), a significantly higher number of additional endoleaks were detected by MRI compared to the population with known endoleaks (22% (95% CI 13-34%) versus 1.9% (95% CI 0.27-12%), $p=0.01$). The pooled proportion of patients with endoleaks was 35% (95% CI: 16-61%) in studies with blood pooling contrast agents (i.e. agents with various degrees of albumin binding such as gadofosveset trisodium and gadobenate dimeglumine) versus 18% (95% CI: 10-30%) in studies using extracellular gadolinium contrast agents ($p=0.21$). Eighty-three percent of additional endoleaks detected by MRI were type II (95% CI 48-96%).

Discussion and Conclusions: MRI detects significantly more endoleaks after EVAR when compared to the routinely used follow-up imaging modalities CTA and DSA, especially type II endoleaks. The detection of type II endoleaks is important in patients with AAA growth >10mm compared to previous examination because of the implications for treatment management. In these patients, treatment (e.g. embolization) has to be considered³. Blood pooling contrast agents may have additional diagnostic value compared to extracellular gadolinium chelates. In conclusion, MRI is a more sensitive imaging modality than CTA for the detection of endoleaks in patients after EVAR.

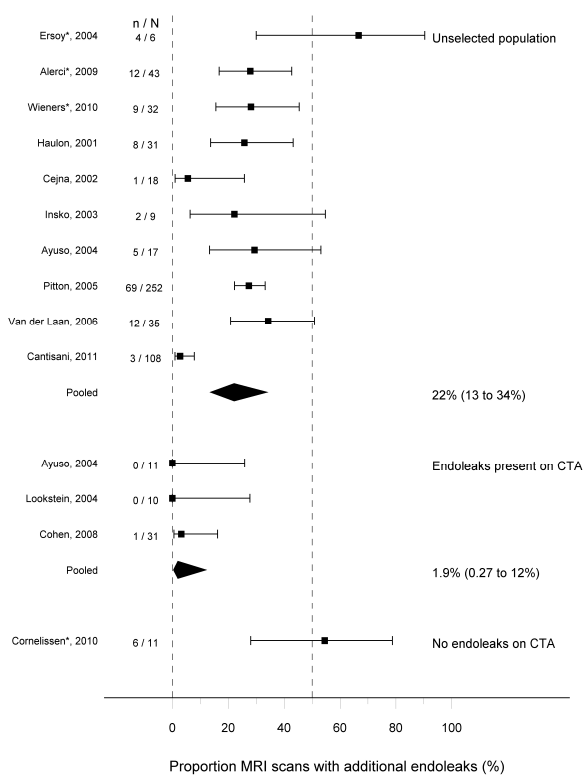


Fig. 1 Forest plot demonstrating additional proportion of endoleaks detected on MRI scans compared to CTA in different patient population

References:

1. Parodi et al. Ann Vasc Surg 1991;5:491-499.
2. White et al. J. Endovasc Surg 1997;4:152-168.
3. Moll et al. Eur J Endovasc Surg 2011;41 Suppl 1:S1-S58
4. Rozenblit et al. Radiology 2003;227:426-433
5. Whiting et al. BMC Med Res Methodol 2003;3:25.