

Blood Flow and BOLD Functional MRI of the Human Retina in Retinitis Pigmentosa: a Preliminary Result

Yi Zhang^{1,2}, Oscar San Emeterio Nateras¹, Joseph M Harrison³, Qi Peng¹, and Timothy Duong^{1,2}

¹Radiology, University of Texas Health Science Center at San Antonio, San Antonio, TX, United States, ²Research Imaging Institute, University of Texas Health Science Center at San Antonio, San Antonio, TX, United States, ³Ophthalmology, University of Texas Health Science Center at San Antonio, San Antonio, TX, United States

INTRODUCTION Retinitis pigmentosa (RP) is a family of retinal diseases characterized by a progressive loss of photoreceptors in the peripheral retina then central retina, eventually resulting in total blindness (1). The RP retina also undergoes extensive vascular and neural remodeling throughout the course of the disease (2). While the genetic aspects of RP are well studied, the lack of non-invasive, depth-resolved imaging techniques has limited the investigation of physiological and metabolic changes of retinal degeneration and their temporal progression in vivo. MRI of the retina offers depth-resolved, and often quantitative and physiological parameters with a large field-of-view. Our group previously reported reduced retinal thickness (3) and blood flow (BF) (4) in the retinas of an animal model of RP. In this study, we describe the challenges and results of applying these approaches to study RP patients. MRI findings are compared with clinical eye exams.

METHODS MR was performed on 3 RP patients (2 F and 1 M, 38±8 yo) and 5 normal subjects (2 F and 3 males, 30±8 yo) on a 3T Philips Achieva with a custom-made surface coil as a receiver. A strategy with alternation of fixations (during data acquisition which has gradient sound) and blinks (during inversion delay which has no gradient sound) via sound cues was used to minimize motion artifacts (5). BF (6) was measured using pseudo-continuous ASL and single-shot turbo spin-echo sequence with TR/TE=4.6s/30ms, slice thickness=6mm, FOV=50x43mm (resolution=500x800µm). BOLD fMRI was acquired during which subjects breathed 1 min air, 1 min pure oxygen and 2 mins air. BOLD fMRI utilized a 2D bSSFP with TR/TE = 15/12 ms, FA= 35°, thk=3mm, FOV = 70x100 mm (150x450µm). Automated profile analysis (5) was performed to align the retina. BF images and BOLD fMRI maps were obtained. Quantitative BF and BOLD % changes were also tabulated over a posterior part of the retina (~±9 mm centered in the macula). In addition, standard clinical eye exams were obtained for RP patients including visual acuity, intra-ocular pressure, fundus image and electroretinography (ERG).

RESULTS ERGs were reduced or not detectable in both eyes of 2 RP patients, with rod ERG signals being more affected than cone ERG signals. For the third RP patient who presented as an unusual unilateral RP case, the diseased eye had reduced ERG responses while the non-RP eye had normal ERG responses. Visual acuity and intra-ocular pressure for all RP patients were unremarkable. Fundus images revealed narrowed retinal arterial vessels and pigmentary migration in peripheral or mid-peripheral regions for all RP patients.

Figure 1 BF images from 2 RP (A, B) and 1 control (D) eyes, with (A) and (C) were from the RP and non-RP eyes of the unilateral RP patient. High BF was localized to the posterior retina and significantly reduced towards the distal edges of the retina. In addition, BF values in RP retinas were lower in macular region and dropped much faster in the peripheral regions compared to BF in control retinas. **Figure 1(E)** shows the grouped averaged BF profiles across the retinal thickness. The group-averaged BF from the posterior retina were 96±52 mL/100mL/min for RP eyes, and 166±47mL/100mL/min for control eyes (mean±SD, P=0.04 between groups, unpaired t-test). **Figure 2** shows the BOLD fMRI maps and signal time courses associated with oxygen challenge from 1 RP (A, B) and 1 control (C, D) subjects. The bSSFP banding artifacts were apparent on the images but they were temporally stable and didn't affect the posterior retina. Robust fMRI responses of the posterior retina were observed in both groups. The group-averaged BOLD signal changes were 6.8±0.1% for RP eyes, and 5.2±0.9% for control eyes (P=0.04 between groups, unpaired t-test).

DISCUSSIONS and CONCLUSIONS This study reports a novel application of MRI to study retinas of RP patients. MRI results showed a significant BF reduction in RP retinas, corroborated by the narrowed retinal arterial vessels on fundus in the same patients. The loss of BF is more severe in the peripheral retina than central retina, consistent with known characteristics of RP. Our results are consistent with previous findings of reduced BF in an animal model of RP using MRI (4), and of significantly reduced retinal perfusion (7) and sub-foveal choroidal perfusion (8) in RP patients by using optically based techniques. Because BF and metabolic function are tightly coupled, it is not surprising that reduced BF is associated with the degenerative process of RP and/or plays a role in its pathogenesis (8).

Our BOLD fMRI results suggest impaired hemodynamic regulation in RP patients (9). A possible explanation of the higher BOLD % changes is that RP retinas produce smaller extent of hyperoxia-induced vasoconstriction compared to control. Alternatively, the loss of high energy-demanding photoreceptors may cause decreased oxygen extraction fraction which could lead to increased BOLD signals during hyperoxia. Together these findings indicate that changes in BF and hyperoxic BOLD response occur before changes in visual acuity. With improvement in spatiotemporal resolution and sensitivity, MRI has the potential to provide unique, clinically relevant, and depth-resolved information for early detection, disease staging and testing novel therapeutic strategies in RP and other retinal diseases.

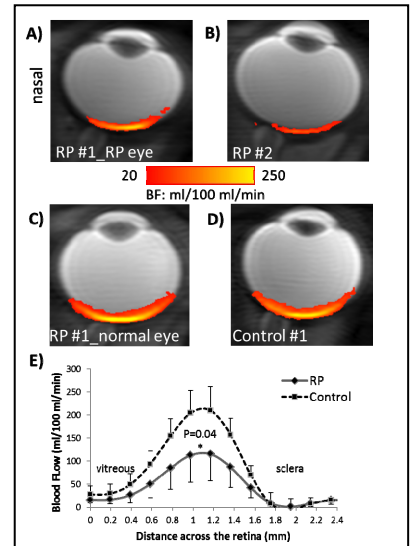


Figure 1: Basal BF (in color) overlaid on scout images from representative 2 RP patients (A, C) and 1 control subject (D). (E) Group-averaged BF profiles across the retinal thickness from RP (solid line) and control subjects (dash line). Error bar: SD.

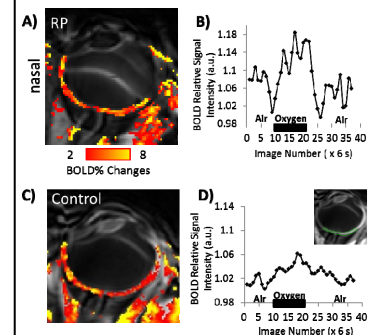


Figure 2: BOLD fMRI response associated with oxygen challenge from a RP (A, B) and a control subject (C, D). (A) and (C) are BOLD percentage signal changes. (B) and (D) are corresponding BOLD fMRI time courses from a posterior part of the retina, demonstrated as a green ROI in the inset image in (D).

References: 1) Hartong, D. T., et al. The Lancet 368: 1795. 2) Marc, R. E., et al. Prog Retin Eye Res 22: 607. 3) Nair, G., et al. JMRI. 2011, Sep 30. 4) Li, Y., et al. IOVS, 50: 1824. 5) Zhang, Y., et al. IOVS, 52: 7232. 6) Peng, Q, et al. MRM, 65: 1768. 7) Grunwald, J. E., et al. American J Ophth, 122: 502. 8) Falsini, B., et al. IOVS, 52: 1064. 9) Cellini, M., et al. Can J Physio Pharm, 88(6):630