

## Identification of living victims of manual strangulation by MR imaging of the neck

Sonja Monika Pivec<sup>1,2</sup>, Eva Scheurer<sup>1,2</sup>, Florian Fischer<sup>1,2</sup>, Gerlinde Komatz<sup>3</sup>, Zoe Voigt<sup>4</sup>, Magdalena Webhofer<sup>5</sup>, Kathrin Yen<sup>6</sup>, and Thomas Ehammer<sup>1</sup>

<sup>1</sup>Ludwig Boltzmann Institute for Clinical-Forensic Imaging, Graz, Austria, <sup>2</sup>Medical University Graz, Graz, Austria, <sup>3</sup>MRI Institute Private Clinic of the Holy Sisters, Graz, Austria, <sup>4</sup>Institute of Legal Medicine and Forensic Science, Charité, Berlin, Germany, <sup>5</sup>Schön Clinic Harthausen, Clinic for Orthopedic Surgery, Germany, <sup>6</sup>Institute for Forensic and Traffic Medicine, University of Heidelberg, Heidelberg, Germany

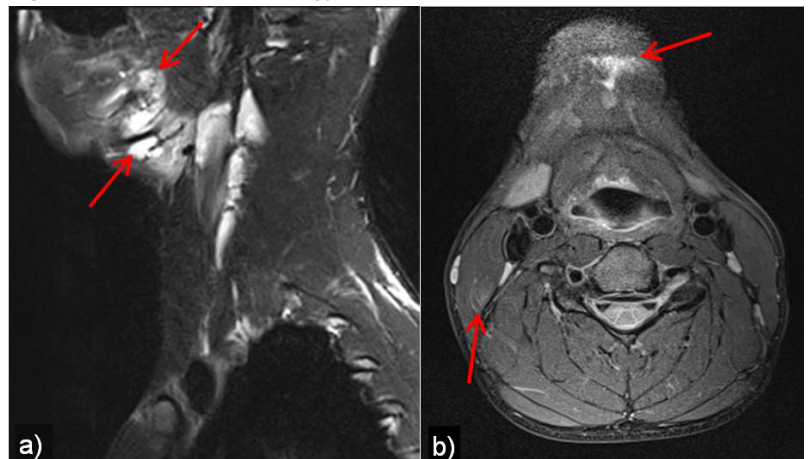
**Introduction:** The diagnosis of strangulation in surviving victims on the basis of objective findings is of crucial importance for the criminal proceeding of the assault. However, to date the gold standard in clinical forensic medicine is an external examination which often shows no injury signs despite a credible history of strangulation. Initial studies using MRI in living and deceased strangulation victims showed that a series of specific, mostly discreet findings could be described in the structures of the neck [1-4]. Nonetheless, radiologic diagnostic criteria for the diagnosis of strangulation remain to be established. The aim of this prospective study was to evaluate the diagnostic performance of a native MRI scan in consideration of strangulation.

**Patients & methods:** 15 subjects (5 males, 10 females; age 27±8 years) who survived a manual strangulation incident (time between incident and MRI 0-6 days, median 1d) and 9 non-injured volunteers (5 males, 4 females; age 37±12 years) including 5 subjects suffering from a respiratory viral infection were enrolled in this study. After an external forensic examination with photo documentation they underwent a native MRI scan on a 3T scanner (Magnetom Trio, Siemens AG, Erlangen, Germany) using a 12-channel head coil, a 4-channel neck coil (Matrix System, Siemens AG, Erlangen, Germany) and a 4-channel phased array carotid coil (Machnet BV, Eelde, The Netherlands) using a defined protocol [(T2: TSE, FS, TE/TR 87/7660ms, slice thickness 3.5-4mm, in 3 orientations) (T1: TSE, TE/TR 10/824ms, slice 3.5mm, coronal) (T1: TSE, FS, TE/TR 11-12/930-1020ms, slice 3.5mm, axial) (T1: MPR, TE/TR 2.2/1800ms, slice 1mm, sagittal) (PD: BB, FS, TE/TR=35/3540ms, slice 3mm, axial)]. The study was approved by the local ethics committee. The MRI data were evaluated by two blinded board certified radiologists, one with and the other without experience in forensic radiology, according to a predefined diagnostic scheme comprising 5 criteria, i.e., subcutaneous edema or bleeding, intramuscular bleeding, lymph node bleeding, bleeding into a salivary gland, and change in vessel wall morphology, of which at least one had to be present for the diagnosis of strangulation. To assess the diagnostic performance of the MRI concerning strangulation sensitivity and specificity, as well as the accuracy and the positive predictive value (PPV) of the test were calculated.

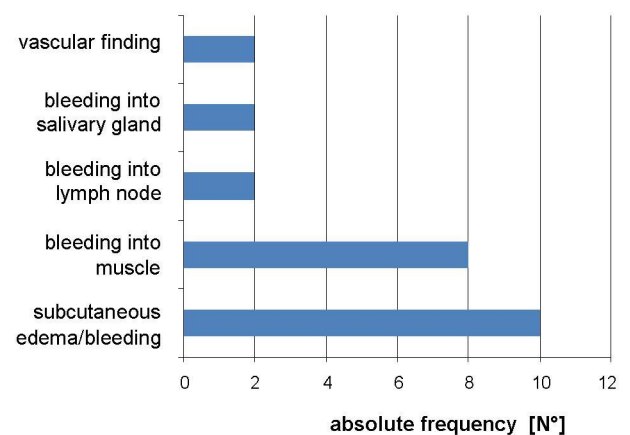
**Results:** After the exclusion of one control due to technical reasons data of 15 strangulation victims and 8 controls were evaluated. Using the above mentioned diagnostic scheme strangulation was detected with a sensitivity of 70% and a specificity of 100%. The accuracy was 80% and the PPV 100%. Fig. 1 shows an example of the good quality imaging data with specific strangulation findings. Fig. 2 shows that subcutaneous lesions and intramuscular bleedings were the most frequent findings occurring in strangulated victims. Inter-observer agreement concerning the diagnosis of strangulation was moderate with  $\kappa=0.56$ . Regarding the detection of specific findings inter-observer agreement was very limited with  $\kappa=0.27$  which can be explained by the fact that the radiologist experienced in forensic radiology detected totally 28 findings compared to only 17 lesions seen by the other observer.

**Discussion & conclusion:** Strangulation in surviving victims was diagnosed in non-enhanced 3T MRI with a high sensitivity and specificity using a diagnostic scheme comprising five criteria. Forensic practice shows that frequently no external signs of strangulation are present, with a history given by the victim that often differs from the assailant's. Therefore, the objective diagnosis of strangulation is a keystone for the criminal proceeding in such cases. In clinical routine no standardized diagnostic and documentation procedures for such patients exists to date. The great differences concerning the detection of the specific and mostly discreet pathological findings between the two radiologists showed that even when using a defined diagnostic scheme experience in forensic radiology is important for optimal diagnostic performance. The objective documentation by MR imaging might offer a new approach to the forensic evaluation of strangulation providing extremely valuable non-invasive data on internal injuries of the neck. MRI in strangulation might become a new gold standard in forensic radiology.

**References:** [1] Yen K et al, Int J Leg Med 2007; 121:115-123. [2] Yen K et al, JMRI 2005; 22:501-10. [3] Christe A, Eur Radiol 2009; 19:1882-9. [4] Christe A, Leg Med (Tokyo) 2010; 12:228-32.



**Fig. 1** Example of strangulation findings in a 20y old male:  
**a)** periossal hematoma bordering the submandibular gland and corresponding to subcutaneous edema (T2 FS sag)  
**b)** submental subcutaneous edema and intramuscular hematoma in the right sternocleidomastoid muscle (PDw FS axial)



**Fig. 2** Absolute frequency of the five findings included in the diagnostic scheme for the detection of strangulation