

Quantitative Cerebral Blood Flow Thresholds May Predict the Absolute Penumbra and Final Infarct Volume Using Bookend DSC-MR PWI Technique with Concentric ROI Analysis

Justin Vranic¹, Parmede Vakil², Ali Habib², Alexander Korutz², Michael C Hurley², Timothy J Carroll², and Sameer A Ansari²
¹Northwestern University, Chicago, IL, United States, ²Northwestern University

Purpose:

One of the purposes of neuroimaging in the setting of hyperacute stroke is to determine tissue that is at risk for infarction, yet potentially reversible (ischemic penumbra) with implications for intravenous or intra-arterial thrombolytic therapy. Traditional MR diffusion/perfusion weighted imaging (DWI/PWI) can depict infarcted tissue and relative regional hemodynamic compromise, but does not provide a quantitative metric of cerebral blood flow (CBF) to delineate the absolute penumbra. Recent studies have suggested that quantitative CBF (qCBF) values may precisely localize ischemic tissue that would benefit from reperfusion therapy and be salvaged from infarction (1). In this study, we explored whether qCBF as measured by the Bookend dynamic susceptibility contrast (DSC-MR PWI) (2) technique can accurately predict the absolute ischemic penumbra or final infarct volume in the hyperacute stroke setting.

Materials & Methods:

Using our institution's PACS and medical record databases, we retrospectively identified and analyzed 7 patients (3M:4F, mean age 64 ± 11 yrs) that suffered a large vessel (ICA/A1-A2 ACA/M1-M2 MCA) thromboembolic occlusion in the anterior intracranial circulation (mean NIHSS 16 ± 9.8), received the MR DWI/PWI using the Bookend DSC-MRI protocol within 8 hours of symptom onset, and follow-up CT imaging at 48-72 hours after presentation confirmed an expanding infarct volume. A trained neuroradiologist mapped regions of interest (ROIs) surrounding the initial infarct volume on DWI, final infarct volume on follow-up CT, and qCBF abnormality on PWI color maps. Both CT and MR DWI/PWI images were coregistered using MATLAB software and qCBF values were calculated in 4 separate concentric ROIs encompassing the initial infarct core, final infarct volume, qCBF abnormality, and normal tissue peripherally. Concentric ROI values were volumetrically extracted cross-sectionally, analyzed among individual patients and averaged for standard deviation analysis.

Results

The average qCBF value of the initial infarct volume was 6.6 ± 2.7 ml/100g/min. The ischemic absolute penumbra, determined by tissue peripheral to the initial DWI core, but internal to the final CT infarct volume, had an average qCBF of 14.5 ± 0.4 ml/100g/min. The false penumbra was tissue identified as abnormal on qCBF color map analysis, but peripheral to the final CT infarct volume, had an average qCBF of 16.9 ± 0.6 ml/100g/min. Finally, normal tissue peripheral to the qCBF abnormality had an average value of 41.5 ± 4.3 ml/100g/min. Figure 1 shows concentric ROI analysis in a patient in a single qCBF (a), DWI (b), and CT (c) slice. Figure 1d shows overlapping initial and final infarct ROIs on a single qCBF slice.

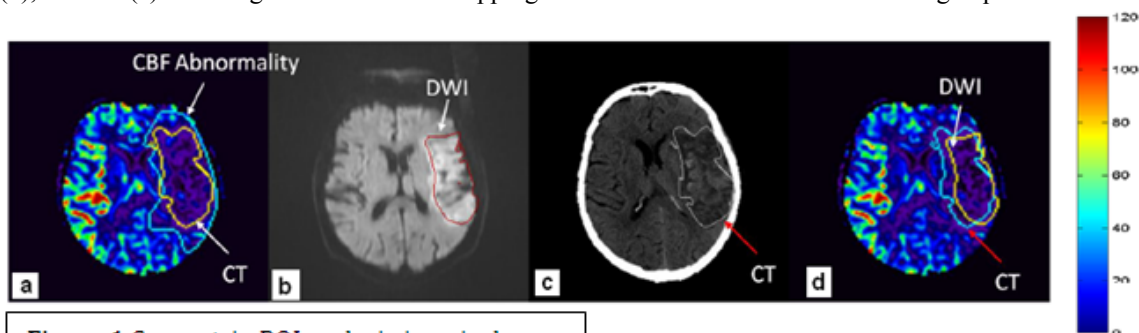


Figure 1 Concentric ROI analysis in a single

Conclusion

Our preliminary study indicates that an appropriate qCBF threshold measurement as determined by the Bookend DSC-MR PWI technique, may serve as a quantitative predictor of the absolute penumbra and final infarct volume. With clinical validation of this technique to accurately assess tissue at risk in the hyperacute stroke setting, thrombolytic therapy may be planned with improved judgment or caution.

References

- 1) Muir et al, Lancet 2006
- 2) Shin W et al MRM 2007