

Microstructural Integrity of the Default Mode Network in Parkinson's Disease

Jeremy Goh^{1,2}, Tracy Melzer^{2,3}, Richard Watts⁴, Michael McAskill^{2,3}, Toni Pitcher^{2,3}, Leslie Livingston^{2,3}, Ross Keenan⁵, Tim Anderson^{2,6}, and John Dalrymple-Alford^{1,2}

¹Department of Psychology, University of Canterbury, Christchurch, Canterbury, New Zealand, ²New Zealand Brain Research Institute, Christchurch, Canterbury, New Zealand, ³Department of Medicine, University of Otago, Dunedin, New Zealand, ⁴College of Medicine, University of Vermont, Burlington, Vermont, United States, ⁵Christchurch Radiology Group, Christchurch, Canterbury, New Zealand, ⁶Department of Neurology, Christchurch Hospital, Christchurch, Canterbury, New Zealand

Objectives: To establish the influence of different stages of cognitive impairment on microstructural integrity of the default mode network in Parkinson's disease (PD).

Methods: Ninety-six PD subjects were classified using detailed cognitive testing as PD with normal cognition (PD-N, n=58), mild cognitive impairment (PD-MCI, n=21), or dementia (PD-D, n=17);¹ thirty-two healthy controls matched for mean age and sex ratio participated. Disease severity was assessed using the UPDRS-III.

Data Acquisition: Both T1-weighted SPGR and diffusion-weighted data were acquired on a 3T GE HDx scanner. The diffusion-weighted spin echo EPI sequence (TE=75.5 ms and TR=13 s) comprised 28 uniformly distributed directions (b=1000s/mm²) and four acquisitions without diffusion weighting. DTIFIT in FSL fit a tensor to eddy current-corrected volumes to generate Mean Diffusivity (MD) and Fractional Anisotropy (FA) maps for each participant. The T1-weighted image was coregistered to the T2-weighted b0 image, segmented, and normalized to a probabilistic elderly brain atlas² using SPM5. This step produced normalization parameters used for data analysis.

Data Analysis: Region-of-interest (ROI) analysis was used to investigate microstructural changes in selected regions of the default mode network (DMN), specifically medial prefrontal, posterior cingulate, and lateral inferior parietal cortex (figure 1). Each ROI was represented as a sphere of radius 4mm (separated into hemispheres in medial prefrontal and posterior cingulate) placed on the average centre MNI coordinate defined by the relevant functional imaging literature. FA and MD values were extracted from ROIs that had been warped into subject specific space using inverse normalization parameters. ANCOVA was used to assess differences between the four groups, with age and education as covariates.

Results: The MD values across the DMN differed significantly across the four groups ($F(3,122) = 6.26, p < 0.001$), with significant post-hoc Newman-Keuls differences between the PD-D group and all other groups, and significant differences between the PD-MCI group and both PD-N and the HC groups, which did not differ (Figure 2). No other significant differences or interactions, including by hemisphere, were evident. No significant differences were found in terms of FA values in the DMN.

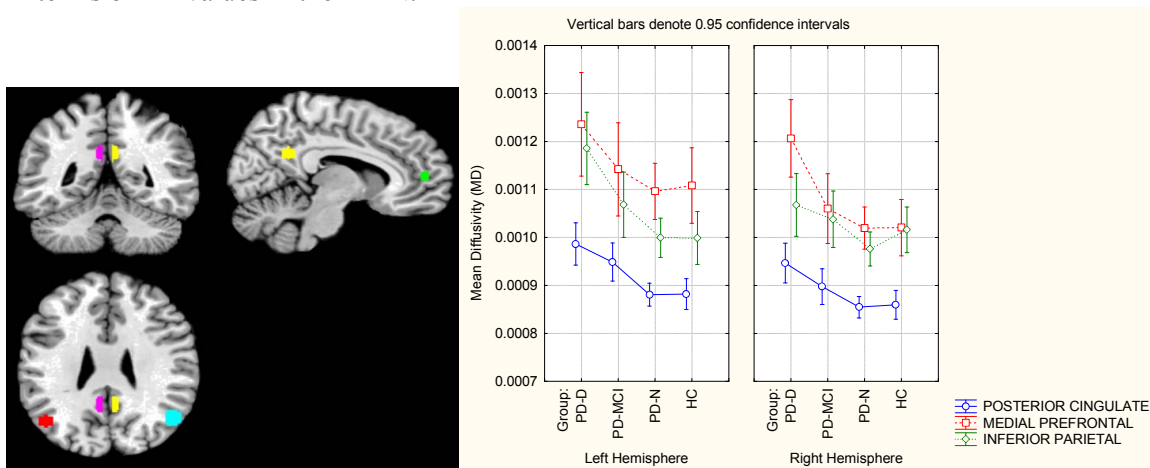


Figure 1 (left): The three regions of interest for the default mode system, analysed using the mean MD and mean FA in the left and right hemispheres.

Figure 2 (right). MD values reflect microstructural impairments in PD-MCI (Parkinson's with mild cognitive impairment) and PD-D (Parkinson's with dementia) compared to PD-N (Parkinson's with normal levels of cognition) and HC (healthy controls).

Discussion: The microstructural integrity of the DMN is compromised in PD with mild cognitive impairment and, especially, when patients meet criteria for PD with dementia. Longitudinal description of these changes will be important to clarify the utility of structural MRI in predicting PD patients at risk of severe cognitive decline.

References: 1. Dalrymple-Alford, J. C., Livingston, L., MacAskill, M. R., Graham, C., Melzer, T. R., Watts, R., & Anderson, T. J. (2011). Characterizing mild cognitive impairment in Parkinson's disease. *Movement Disorders*, 26(4), 629-36.