

Patterns of regional gray matter atrophy associated to PASAT and SDMT performances in relapsing remitting multiple sclerosis patients

Gianna Riccitelli¹, Maria A. Rocca¹, Elisabetta Pagani¹, Vittorio Martinelli², Marta Radaelli², Andrea Falini³, Giancarlo Comi², and Massimo Filippi¹
¹Neuroimaging Research Unit, Institute of Experimental Neurology, San Raffaele Scientific Institute and Vita-Salute San Raffaele University, Milan, Italy, Italy, ²Department of Neurology, San Raffaele Scientific Institute and Vita-Salute San Raffaele University, Milan, Italy, Italy, ³Department of Neuroradiology, San Raffaele Scientific Institute and Vita-Salute San Raffaele University, Milan, Italy, Italy

Background. The symbol digit modalities test (SDMT) has been proposed as a promising alternative to the paced auditory serial addition test (PASAT) to evaluate sustained attention, concentration and speed of information processing in multiple sclerosis (MS).

Objective. To investigate the relationship between performance at PASAT and SDMT and the patterns of regional gray matter (GM) atrophy in patients with relapsing remitting (RR) MS.

Methods. Using a 3.0 Tesla scanner, three-dimensional (3D) T₁-weighted images were acquired from 51 RRMS patients. All patients were evaluated with PASAT and SDMT tests. Using SPM8 and DARTEL (1), VBM (2) was performed for the GM. A regression analysis was used to investigate the correlations between regional GM atrophy and the PASAT as well as the SDMT test. GM regions commonly atrophied during the performance of the PASAT and SDMT were investigated using a conjunction analysis, while GM regions selectively atrophied during each of the two tests were investigated using an exclusively masking procedure.

Results. In RRMS patients, poor PASAT performance was associated with GM atrophy in the bilateral caudate nucleus, left cingulum, right inferior frontal gyrus (IFG), bilateral middle frontal gyrus (MFG), right superior frontal gyrus (SFG), right middle temporal gyrus (MTG), bilateral superior temporal gyrus (STG), bilateral postcentral gyrus, right supramarginal gyrus, left inferior parietal lobule (IPL), right superior parietal lobule (SPL), right middle and superior occipital gyri, and bilateral cerebellum (r values ranging from 0.48 to 0.64). Performance at SDMT correlated with GM atrophy in the left cingulum, right postcentral gyrus, left IPL, left SPL and bilateral cerebellum (r values ranging from 0.47 to 0.68). Common regions of GM atrophy were detected in the left cingulum, left IPL, and left cerebellum (conjunction analysis, $p < 0.05$ FWE corrected). PASAT performance was associated with selective atrophy in the bilateral caudate nucleus, left MFG, right STG, right supramarginal gyrus, and left IPL, while SDMT performance had a selective association with atrophy in the right cerebellum.

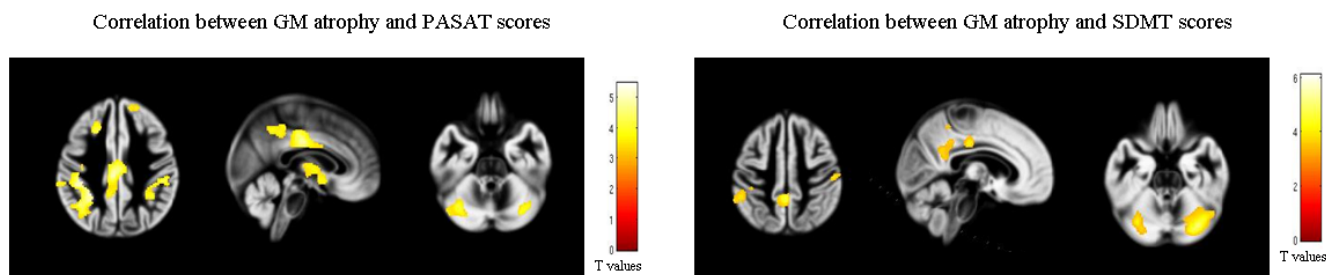


Figure 1. Clusters of significant GM atrophy (in yellow) in RRMS patients correlated with PASAT and SDMT performances.

Conclusions. Deficits at SDMT and PASAT are associated to distinct patterns of regional distribution of GM atrophy in patients with RRMS.

References.

1. Ashburner J. Neuroimage 2007;38:95-113. 2. Ashburner J. Magn Reson Imaging. 2009;27:1163-74.

Study funding. This study was partially supported by a grant from FISM/2008/R/13 (P.I.: Massimo Filippi).