

Abnormalities of Resting State Functional Connectivity in Patients With Pediatric Multiple Sclerosis

Maria A. Rocca¹, Paola Valsasina², Martina Absinta², Angelo Ghezzi³, Lucia Muiola⁴, Pierangelo Veggiotti⁵, Andrea Falini⁶, Giancarlo Comi⁴, Massimo Filippi², and the MS and Neuroimaging Study Groups of the Italian Neurological Society⁷

¹Neuroimaging Research Unit, Institute of Experimental Neurology, San Raffaele Scientific Institute and Vita-Salute San Raffaele University, Milan, Italy, Italy, ²Neuroimaging Research Unit, Institute of Experimental Neurology, San Raffaele Scientific Institute and Vita-Salute San Raffaele University, Milan, Italy, ³MS Centre, Ospedale di Gallarate, ⁴Department of Neurology, San Raffaele Scientific Institute and Vita-Salute San Raffaele University, Milan, Italy, ⁵Department of Child Neurology and Psychiatry, Fondazione IRCCS Istituto Neurologico C Mondino, Pavia, Italy, ⁶Department of Neuroradiology, San Raffaele Scientific Institute and Vita-Salute San Raffaele University, Milan, Italy, ⁷.....

Introduction. Previous active functional magnetic resonance imaging (fMRI) studies have investigated the function of the motor system in patients with pediatric multiple sclerosis (MS) vs. controls [1]. Resting state (RS) functional connectivity (FC) in these patients has never been explored.

Objective. Aim of this study was to explore abnormalities of FC and of functional interaction among resting state networks (RSNs) in patients with pediatric multiple sclerosis (MS), as well as their correlation with clinical variables and T2 focal lesions.

Methods. Brain dual-echo and RS fMRI scans were acquired from 38 pediatric MS patients and 18 age-matched controls. T2 lesion volume (T2LV) was assessed on dual-echo images. Independent component analysis (ICA) [2] and a template-matching procedure were used to identify RSNs with potential functional relevance. Within-group and between-group FC comparisons were performed with SPM8. The functional network connectivity (FNC) toolbox [3] was used to assess changes of interactions among RSNs. In MS patients, correlations between network abnormalities, clinical and conventional MRI variables were also assessed.

Results. RSNs of interest included two sensorimotor RSNs, two visual RSNs, one auditory RSN, two components resembling the default mode network (DMN), one executive control network (ECN), one salience network (SN), two working memory networks (WMN) and one attention network (Figure).

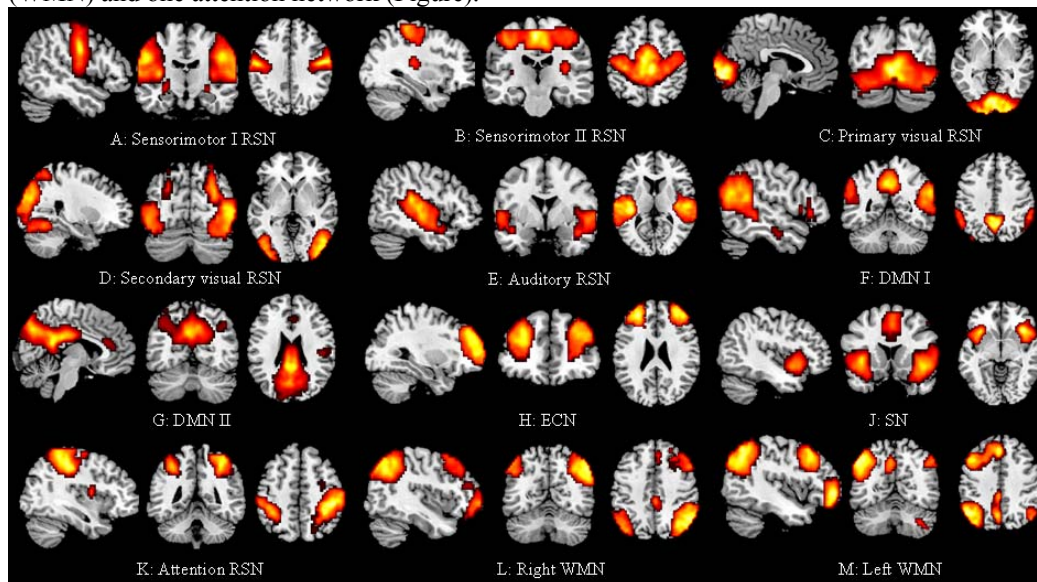


Figure legend.

RSNs with potential functional relevance detected in our study subjects (ANOVA model, *t* test thresholded for positive values, $p < 0.05$ family-wise error corrected for multiple comparisons). A,B: sensorimotor networks; C,D: visual networks; E: auditory network; F,G: DMNs; H: ECN; J: SN; K: attention network; L,M: right and left WMN.

Significant RS FC abnormalities were detected in several RSNs of pediatric MS patients vs. controls. A decreased FC was found in the left (L) secondary somatosensory cortex (SII) and L cerebellum of the sensorimotor RSNs ($p=0.04$ and $p=0.009$, respectively), and in the cuneus of the primary visual RSN ($p=0.04$). In addition, pediatric MS showed decreased FC in the posterior cingulate cortex (PCC) and in parietal and temporal regions of the DMN, ECN, SN and WMNs (p ranging from 0.007 to 0.04). Conversely, increased FC was found in inferior and superior frontal regions of the SN and DMN ($p=0.04$ and 0.01, respectively).

Decreased FC of the PCC was significantly correlated with the expanded disability status scale (EDSS) score ($r=-0.48$, $p=0.002$). A moderate correlation was also found between decreased FC of the superior temporal gyrus and disease duration ($r=-0.31$, $p=0.05$). No significant correlation was found between RS FC and T2LV.

FNC analysis revealed only limited differences of inter-network connectivity between pediatric MS patients and controls, with a decreased connectivity between the sensorimotor RSN and the ECN, and an increased connectivity between the auditory and the attention RSNs.

Conclusion. Significant RS FC abnormalities occur in patients with pediatric MS. Decreased RS FC seems to be associated with a more severe clinical disability and a longer disease duration.

References. [1] Rocca MA et al., Hum Brain Mapp 2009;30:2844-51. [2] Calhoun V et al., Hum Brain Mapp 2001;14:140-151. [3] Jafri M et al., Neuroimage 2008;39:1666-81.

This work has been partially supported by a grant from Italian Ministry of Health (GR-2009-1529671)