

Striatum-Motor Network Functional Connectivity Deficits in Amyotrophic Lateral Sclerosis: A Resting State fMRI Study

Ming Zhang¹, Pan Lin², Chenwang Jin¹, Cuiping Mao¹, Chen Niu¹, ZhiGang Min¹, Jingxia Dang³, Qiaoting Jin³, and Xin Liu²

¹Department of Medical Imaging, the First Affiliated Hospital of Medical College, Xian Jiaotong University, Xi'an, Shaanxi, China, People's Republic of, ²Key Laboratory of Biomedical Information Engineering of Education Ministry, Xian Jiaotong University, Xi'an, Shaanxi, China, People's Republic of, ³Department of Neurology, the First Affiliated Hospital of Medical College, Xian Jiaotong University, Xi'an, Shaanxi, China, People's Republic of

Introduction

Amyotrophic lateral sclerosis (ALS) is a progressive neurodegenerative disease characterized by deficits in motor systems, which are associated with loss of upper and lower motor neurons [1]. The use of resting state functional magnetic resonance imaging (fMRI) has shown sensorimotor functional connectivity (FC) deficits in ALS [2-3]. Striatum-motor network has found to play an important role in motor control [4-5]. Whether the fluctuations of resting state fMRI signal within striatum-motor network functional connectivity is associated with abnormal neuronal activity remains unclear. In this study, we specifically investigated whether patients with ALS are associated with dysfunction of interregional functional connectivity in striatum-motor network that support motor function.

Methods

MRI acquisition: Seven patients with ALS and Seven age-matched healthy control groups participated in this study. A 3.0 T GE scanner equipped with an eight-channel multi receive system was used. Structural images (3D FSPGR 1x1x1 mm³, 140 slices) and BOLD EPI data (TR/TE = 2500/40 ms, flip angle=90°, matrix size=64x64, 3mm slice thickness) were acquired. For the resting state fMRI data acquisition, each participant was asked to keep their eyes closed and not to think of anything in particular. **fMRI data Analysis:** fMRI analysis was performed in AFNI (Cox, 1996) and FSL software. Pre-processing consisted of motion correction, temporal band-pass filtering (0.008 Hz < f < 0.08 Hz), spatial normalization to standard Talairach space and spatial smoothing (Gaussian, FWHM 6mm). Several sources of nuisance covariates (six head motion parameters, signal from the white matter, the CSF and whole brain global mean signal) were eliminated using linear regression. To define key seeds of the striatum-motor network, the major brain regions of interest within striatum-motor network were taken from AAL template. The seed regions including bilateral caudate, putamen, pallidum, postcentral and precentral cortex. The cross-correlation analysis was calculated by extracting the BOLD time course from each region within striatum-motor network, then computing the correlation coefficient between that time course and the time course from all other brain regions. Temporal correlation coefficients relative to each seed were converted to z-scores by using Fisher's r-to-z transformation, then one sample t-tests were performed to create a group correlation map. To evaluate inter-region FC alteration within striatum-motor network between ALS patients and healthy groups, signal were then estimated by averaging the time series of all voxels in each striatum-motor network region. The Pearson's correlation coefficients were calculated between each pair of striatum-motor network regions for each subject. To further evaluate the alteration of functional connectivity within striatum-motor network, we performed the two-sample t tests (p < 0.05) on pairwise correlation matrix of striatum-motor network between patients and normal subjects.

Results and Discussion

Each seed region within striatum-motor network functional connectivity map between patients with ALS and control subjects show significant difference (see Figure 1), patients with ALS demonstrated relatively abnormal interhemispheric functional connectivity within striatum-motor network. By comparison, patients demonstrated decrease interhemispheric motor functional connectivity. Figure 2 shows that intra and inter interhemispheric functional connectivity strength between caudate and postcentral/precentral cortex significantly increase within patients compare with normal subjects. A possibility is that increased functional connectivity strength between caudate and motor cortex (postcentral/precentral cortex) reflects the striatum-motor network reorganization. For the patients with ALS, the caudate interhemispheric functional connectivity shows decrease. We also found the intrahemispheric functional connectivity within motor regions (bilateral Postcentral and Precentral) significantly decrease in ALS patients compare with normal subjects (p < 0.05). This study indicated that ALS patients are associated with functional connectivity alteration of brain striatum-motor network.

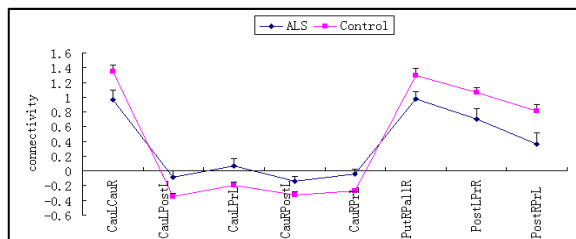


Figure 2. Strength of functional connectivity within striatum-motor network between ALS and control groups.

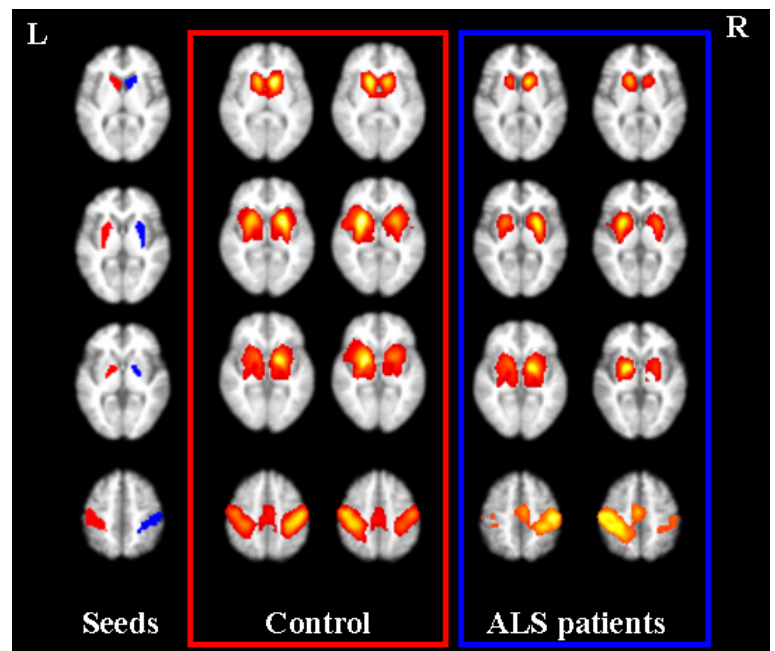


Figure 1. Functional connectivity map of each striatum-motor network seed region between patients with ALS and controls (threshold of p < 0.05 family-wise error correction).

Acknowledgments: This research work was supported by National Natural Science Foundation of Peoples's Republic of China (No.81171318, No.30870686) and the Fundamental Research Funds for the Central Universities.

References: [1] EllisGM et al., Neurology, 57: 1571-1578, 2001.[2] Agosta F et al., Cerebral cortex, in press. [3] Esther V et al., Plos ONE:5(10): e13664; 2010. [4] Mohammadi B et al., Exp Neurol, 217:147-53, 2009. [5] Robinson S et al., BMC Neurosci, 23, 10:137, 2009.