

Clinical significance of lipid peak in in-vivo 1H-MR spectroscopy of uterine sarcomas at 3T

Mayumi Takeuchi<sup>1</sup>, Kenji Matsuzaki<sup>1</sup>, and Masafumi Harada<sup>1</sup>

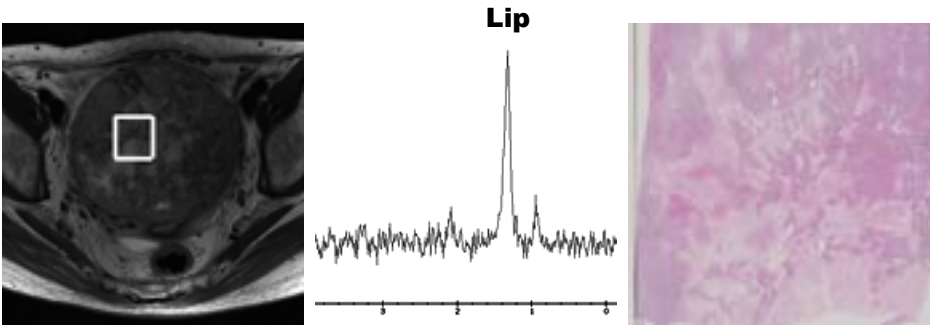
<sup>1</sup>Department of Radiology, University of Tokushima, Tokushima, Tokushima, Japan

**[Introduction]** Typical uterine leiomyomas and adenomyotic lesions may show low signal intensity on T2-weighted images, however, some lesions may show heterogeneous or high signal intensity and to distinguish them from uterine sarcomas is often difficult. 1-H MR spectroscopy (MRS) provides metabolic information, which is useful for the differentiation of benign and malignant tumors. The choline peak (3.2 ppm) may be observed in solid tumoral components reflecting metabolic activity of tumor cells, and tend to show higher peaks in malignant tumors. Takeuchi et al. evaluated the choline concentration in uterine corpus tumors and found significantly higher choline concentration in malignant lesions (endometrial cancers and sarcomas) than in benign lesions (endometrial hyperplasia and polyps; leiomyomas; adenomyotic lesions) (Eur Radiol 21; 2011). However, high-grade sarcomas often show massive necrosis and may cause low choline concentration due to the decrease of viable tumor cells. The lipid peak (1.3 ppm) is observed in malignant tumor with necrosis (Delikatny et al. NMR Biomed 24; 2011) such as uterine cervical cancer in gynecologic tumors (Mahon et al. NMR Biomed 17, 2004; Lyng et al. BMC Cancer 7, 2007), whereas normal tissue and most of benign tumors do not show high lipid peak associated with necrosis. We hypothesized that high concentration of lipid may suggest high-grade malignancy with necrosis such as uterine sarcomas, and may contribute to distinguish sarcomas from benign myometrial lesions.

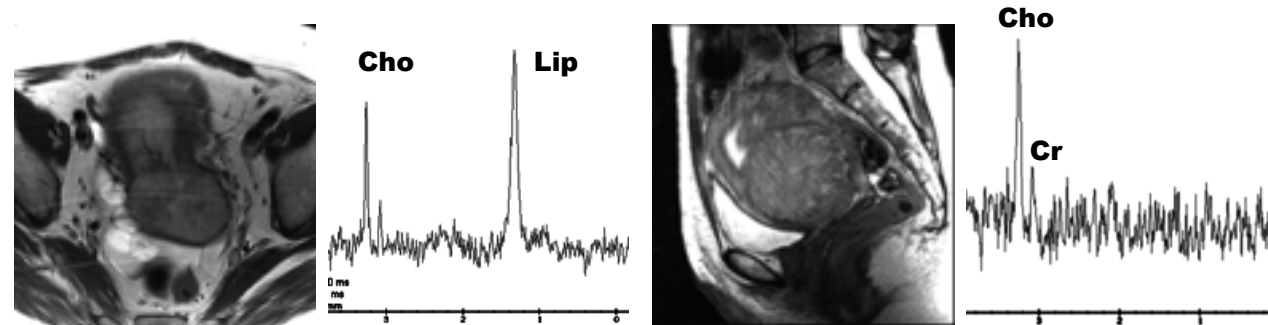
**[Materials and Methods]** Pathologically diagnosed 14 uterine sarcomas and 24 benign myometrial lesions (23 leiomyomas including 4 cellular leiomyomas; 1 atypical polypoid adenomyoma) were retrospectively evaluated. MRS (PRESS, TR/TE = 2000ms/144ms) was performed in all subjects on a system with a 3T superconducting units (Signa HDx 3T, General Electric, Milwaukee, WI) with 8ch body-array torso coils. Single voxel of interest (VOI=8ml) was placed on solid tumoral components for heterogeneous lesions so as not to contain cystic or necrotic areas as much as possible by referring T2WI, T1WI and DWI. The coline and lipid peaks were visually evaluated. The metabolite concentration level was classified into three classes; that is, twofold higher than the average noise level (high), higher than the average noise level but lower than a twofold higher noise level (low), and the same as the average noise level (none).

**[Results]** The lipid peaks were observed in all 14 sarcomas (high 12; low 2), whereas in 7 of 24 benign lesions (high 1; low 6). One benign lesion with high lipid peak was lipoleiomyoma (benign leiomyoma with fatty metaplasia) and fatty components were visualized on T1WI. In 6 benign lesions with low lipid peak contained 3 cellular leiomyomas and one atypical polypoid adenomyoma. The choline peaks were observed in 12 of 14 sarcomas (high 9; low 3), whereas in all 24 benign lesions (high 20; low 4). 2 sarcomas with no choline peak showed high lipid peak, and histological examination revealed that VOIs were placed in the areas of almost coagulated necrosis in this 2 lesions.

**[Conclusions]** High lipid peak from necrosis is not observed in benign myometrial lesions, so the presence of high lipid peak may suggest high-grade sarcoma with necrosis. However massive necrosis in sarcomas may decrease the choline peak, the presence of high lipid peak may suggest their malignant nature. We conclude that high lipid peak in uterine mass without fatty component is suggestive for sarcoma, whether the choline peak is present or not.



**Fig. 1:** Leiomyosarcoma shows high lipid peak but no choline peak on MRS. Histological examination revealed that VOI was placed in the areas of almost coagulated necrosis.



**Fig. 2:** Undifferentiated endometrial sarcoma shows bimodal high peaks of choline and lipid on MRS.

**Fig. 3:** Leiomyoma shows high signal intensity on T2WI. MRS shows choline and creatine peaks, and no lipid peak is observed.