

1H MAGNETIC RESONANCE SPECTROSCOPY(MRS) OF ENDOMETRIAL CARCINOMA AND NORMAL ENDOMETRIUM OF CHILDBEARING WOMEN IN DIFFERENT MENSTRUAL CYCLE

Xiaoduo Yu¹, Yan Chen¹, Meng Lin¹, Han Ouyang¹, and Chunwu Zhou¹

¹Department of Diagnostic Radiology, Cancer Hospital & Institute, Chinese Academy of Medical Sciences & Peking Union Medical College, Beijing, Beijing, China, People's Republic of

Objective: To analyze the ¹H MR spectroscopic features of endometrial carcinoma and normal endometrium of childbearing women in different menstrual cycle and to investigate the ability of the choline (Cho) peak value in diagnosis of endometrial carcinoma.

Materials and methods: Examination were performed in 15 patients with endometrial carcinoma confirmed histopathologically and normal endometrium in 27 cases of childbearing women in different menstrual cycle. A single-voxel ¹H MRS was performed by point-resolved spectroscopic (PRESS) technique with TR/TE=1500/35msec on 3.0T MR scanner (GE, Signa HDx, America) with 8-channel phase-array body coil. The volume of interest for MRS measurement was located in the tumor of the patient and normal endometrium of the childbearing women. The value of Cho peak (3.2ppm) was calculated by SAGE software at the workstation (version 4.4, GE). Firstly, use independent samples T-test and paired samples T-test to compare the differences of Cho peak value among those three groups. Then taking the two normal groups as control group respectively, ROC was conducted to analyze the ability of Cho peak value to diagnose the endometrial carcinoma. The two ROC were compared by Medcalc software (version 12.0). **Results:** Finally, 13 patients (age range, 42-60 years) and 16 cases (age range, 23-39 years) of normal group both in secretory endometrium (1-4 days before menses) and proliferative endometrium (1-2 days after menses) with high resolution and measurable Cho peak were included. The Cho peak value of endometrial carcinoma, normal endometrium in secretory phase and in proliferative phase were $(3.84 \pm 2.04) \times 10^6$, $(2.03 \pm 1.07) \times 10^6$ and $(6.92 \pm 3.29) \times 10^6$ respectively. There were statistical difference between the Cho peak value of endometrial carcinoma and those of normal endometrium in secretory phase ($p=0.002$), and between endometrial carcinoma and normal endometrium in proliferative phase ($p<0.001$), also between normal endometrium in those two phase ($p<0.001$). When using the two normal groups as control, based on ROC analyses the AUC was 0.817 (95% CI, 0.630-0.935) and 0.966 (95% CI, 0.824-0.999) with statistical difference ($z=2.324$, $P=0.02$).

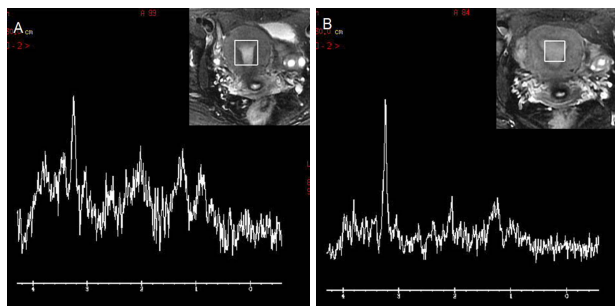


Figure1 MRS in a 30-year-old woman with normal endometrium in proliferative phase (A) and in secretory phase (B), the Cho peak value were 3.17×10^6 and 7.37×10^6 respectively.

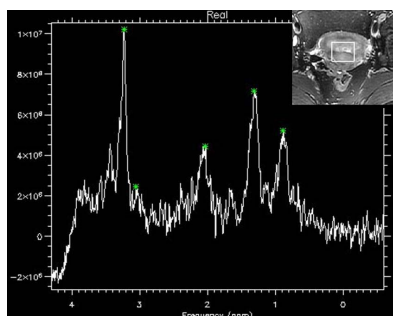


Figure2 MRS in a 48-year-old woman with endometrial carcinoma showed an irregular mass on the uterine cavity with higher Cho peak of 10.23×10^6 .

Conclusion: Cho peak value on ¹H MRS at 3.0T has utility to provide insights into the metabolism of normal and abnormal endometrium at molecular level, and are helpful in diagnosis of endometrial carcinoma. To childbearing woman with suspicious endometrial carcinoma, examination in proliferative phase will be benefit to make accurate diagnosis.