

## Functional MR Imaging of Kidneys

Eito Kozawa<sup>1</sup>, Tsutomu Inoue<sup>2</sup>, Waka Mizukoshi<sup>3</sup>, Naoko Nishi<sup>4</sup>, Hiromichi Suzuki<sup>2</sup>, and Fumiko Kimura<sup>3</sup>

<sup>1</sup>Imaging Diagnosis, Saitama Medical University, International Medical Center, Hidaka-shi, Saitama, Japan, <sup>2</sup>Nephrology, Saitama Medical University, Japan,

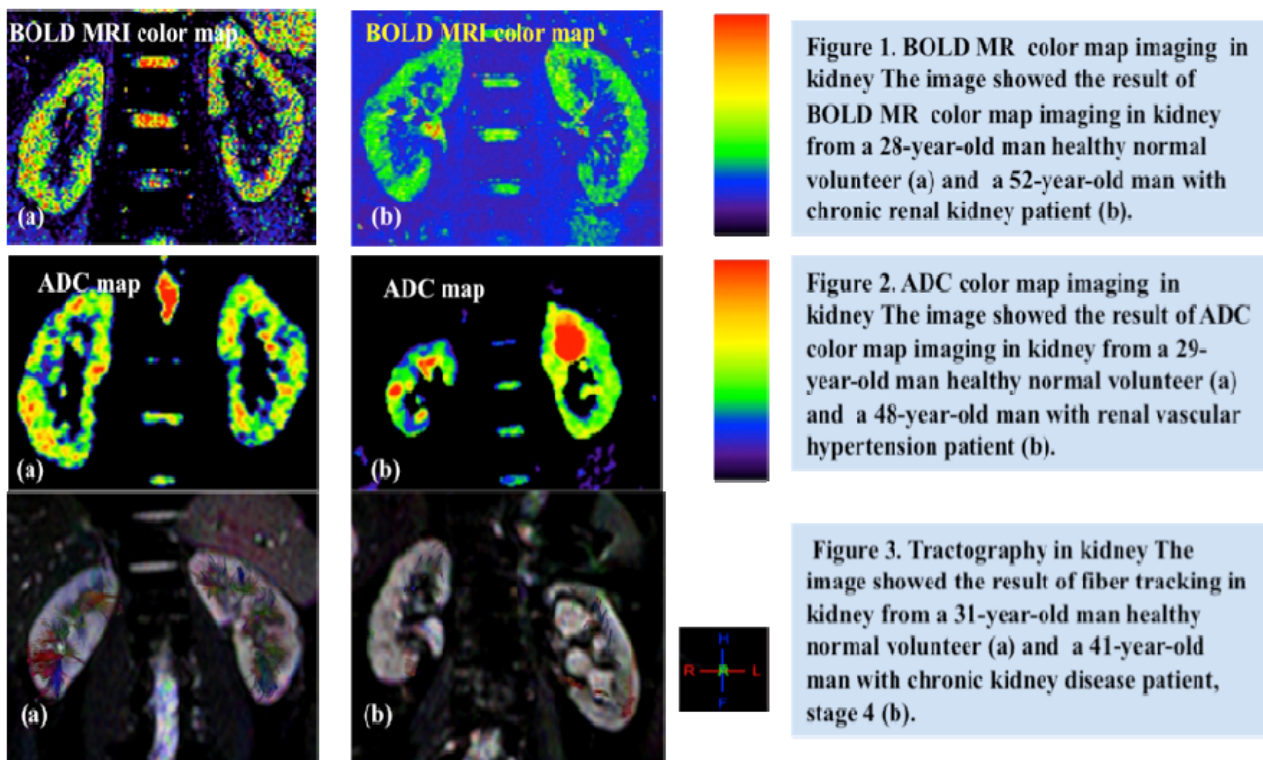
<sup>3</sup>Imaging Diagnosis, Saitama Medical University, International Medical Center, Japan, <sup>4</sup>Saitama Medical University, International Medical Center, Japan

### Purpose

- 1) To review the technique of blood oxygen level-dependent (BOLD) MR imaging, diffusion-weighted (DW) MR imaging and diffusion tensor imaging (DTI) for kidney disease
- 2) To demonstrate the added value of blood oxygen level-dependent (BOLD) MR imaging, DW MR imaging and diffusion tensor imaging (DTI) for kidney disease

### Outline of Content:

1. The appearance of normal kidney on BOLD MR imaging, DW MR image and DTI.
2. Usefulness and limitation of BOLD MR imaging for kidney disease.
3. Usefulness and limitation of DW MR imaging for kidney disease.
4. Usefulness and limitation of diffusion-weighted imaging and DTI.



### Summary:

Functional MR imaging of kidneys in the assessment of the indeterminate renal disease can provide additional valuable information. The aim of the exhibit is to highlight the usefulness of functional MR imaging of kidney.