

A reinvestigation of the feasibility and reproducibility of perfusion MRI in the kidneys

Wen-Chau Wu^{1,2}, Mao-Yuan Su³, Chin-Cheng Chang³, and Kao-Lang Liu³

¹Graduate Institute of Oncology, National Taiwan University, Taipei, Taiwan, ²Graduate Institute of Biomedical Electronics and Bioinformatics, National Taiwan

University, Taipei, Taiwan, ³Medical Imaging, National Taiwan University Hospital, Taipei, Taiwan

Introduction

Several studies have suggested the diagnostic value of renal blood flow (RBF) in nephropathy (1). With MRI, arterial spin labeling (ASL) imaging and dynamic contrast enhanced (DCE) imaging are two established techniques for perfusion measurement although their feasibility in the kidneys is still under investigation (2,3). One major challenge is glomerular filtration of the tracers used (water for ASL and Gd-DTPA for DCE). Extended biophysical models have been proposed to account for dual outputs and/or inputs of tracers in the cortex and medulla. These methods usually require additional scans for parameter estimation (i.e., longer examination time) in addition to higher demand for contrast-to-noise ratio (CNR) that we found marginal, particularly in the medulla, even for original models of less unknowns to fit. In this study, we assessed the reproducibility of ASL and DCE in RBF measurement using the original models and examined their CNR both in time and in space. Technical limitations were discussed.

Materials and Methods

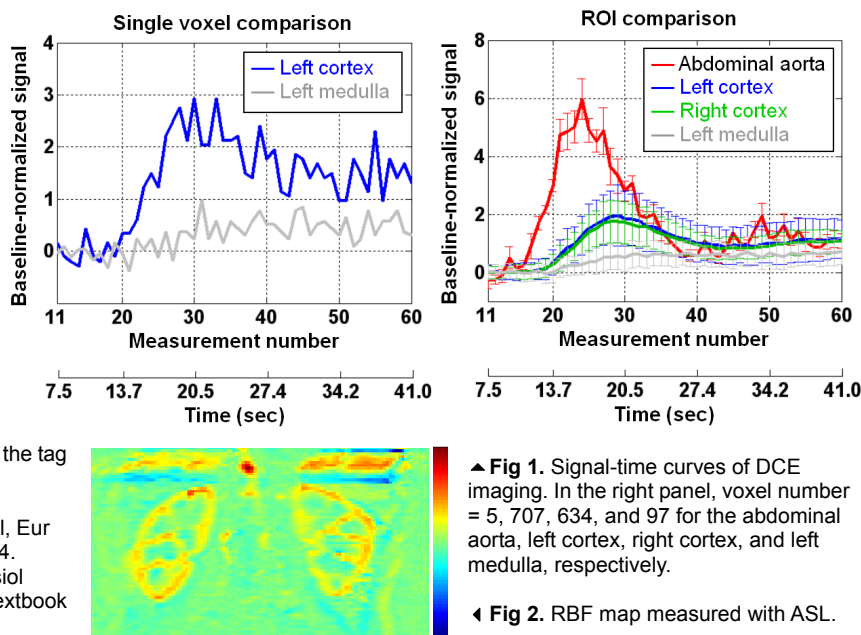
Four healthy adults (F/M = 2/2, age = 25-30 yrs) were included in this IRB-approved study. All participants provided written informed consent. MR imaging was performed on a 3T Tim Trio Siemens system using the spine matrix coil and a flexible torso matrix coil for signal reception, and the body coil for RF transmission. Pseudocontinuous ASL was adopted for its optimal balance between labeling efficiency and signal-to-noise ratio (4). Imaging parameters were: labeling duration = 1.5 s, post-labeling delay = 1 s, slice thickness = 6 mm, 5 coronal slices, single-shot EPI readout (matrix = 128x64, voxel size = 2.6x5.2x6-3.1x6.2x6 mm³, GRAPPA acceleration factor = 2, TR = 3 s, TE = 17 ms). The labeling plane was axial and 70-90 mm above the center of the imaging volume such that it was approximately perpendicular to the abdominal aorta. Ten runs of ASL were conducted and each comprised 6 measurements with the first 2 discarded. The duration of breath holding was thus no longer than 18 s. For DCE imaging, 0.0125 mmol/kg of Gd-DTPA was injected at a rate of 4 ml/s using a power injector followed by a 15 ml saline flush. Saturation-recovery (SR) turbo FLASH was used for image acquisition (slice thickness = 8 mm, 2 coronal slices plus 1 axial slice, post saturation delay = 150 ms, flip angle = 10°, matrix = 192x155, voxel size = 1.7x2.1x8-2.1x2.6x8 mm³, GRAPPA acceleration factor = 2, TE = 0.98 ms, 228 ms per slice), which started 5 measurements before the injection of contrast media and last for 75 measurements afterward. The first 5 measurements were discarded. The subject was instructed to hold their breath as long as she or he could. ASL was performed before DCE in the back-to-back experiment, which was repeated after 2.5 hours. The mean half-life of elimination phase of Gd-DTPA has been determined to be 1.58±0.13 hours at doses of 0.1 and 0.25 mmol/kg (5). Given that we used a ten-fold lower dose, the carry-over effect is expected to be negligible after 2 hours. RBF_{ASL} was calculated from the signal difference between the tag and control images, using the abdominal aorta as an internal reference. $RBF_{DCE} = [C_t(t) \otimes^{-1} C_a(t)]_{t=0}$ where \otimes^{-1} denoted deconvolution. $C_t(t)$ and $C_a(t)$ were the concentration-time curves of tissue and the abdominal aorta, respectively, and $C(t) \propto (S(t) - S_0)/S_0$. S_0 was the average signal intensity before the arrival of contrast agent. $C_a(t)$ was estimated on the axial slice through the abdominal aorta. Second-pass and motion related signal fluctuations were removed by gamma-variate curve fitting. Both kidneys in the slice where they were most clearly seen were segmented into cortex and medulla, from which average RBF of both kidneys was calculated for the cortex and medulla subject by subject. Reproducibility was evaluated by within-subject coefficient of variation (wsCV).

Results and Discussion

Fig 1 shows the signal-time curves of DCE from a representative subject. In the left panel, CNR is about 10 in the cortex and below 3 in the medulla, suggesting that measurement of medullary flow may not be possible on a voxel-wise basis and is advised to perform ROI-based calculation (see the right panel). The contrast bolus takes about 1.2 sec to travel from the abdominal aorta to the cortex, and another 1 sec to the medulla. A transit time of 2.2 sec yields marginal flow contrast for ASL imaging. Indeed, as shown in Fig 2, CNR of (11.2 in the cortex and 3.4 in the medulla) is barely sufficient for separating the medulla from background. When averaged across subjects, cortical RBF_{ASL} is ~15% lower than cortical RBF_{DCE}. Given that on average 20% of intravascular water carried to the kidneys is filtered out by glomeruli (6), about 6% of the Gd-DTPA was filtered out during the first pass. Such an amount of contrast loss should not affect the DCE quantification, also suggesting that dual inputs may not be necessary in modeling medullary flow. The wsCV was 7.9% in the cortex and 7.2% in the medulla with ASL, and 9.6% in the cortex and 19.1% in the medulla with DCE. Because CNR is low in the medulla, the measured wsCV is more meaningful for the cortex. In summary, cortical RBF measurement is feasible with DCE using single-input-single-output models whereas ASL quantification needs to account for tag loss through glomerular filtration. Both ASL and DCE measurements are reproducible in the cortex. To quantify medullary RBF, higher doses of contrast media may be an option for DCE although it can cause signal saturation in the aorta and confound flow quantification. One way to increase CNR for ASL is using background suppression (7) although the tag loss caused by nonideal inversion should be considered.

References

1. Notohamiprodjo et al, JMRI 2010;31:490.
2. Vallee et al, Eur Radiol 2000;10:1245.
3. Robson et al, MRM 2009;61:1374.
4. Wu et al, MRM 2007;58:1020.
5. Weinmann et al, Physiol Chem Phys Med NMR 1984;16:167.
6. Guyton and Hall textbook of Medical Physiology.
7. Garcia et al, MRM 2005;54:366.



▲ Fig 1. Signal-time curves of DCE imaging. In the right panel, voxel number = 5, 707, 634, and 97 for the abdominal aorta, left cortex, right cortex, and left medulla, respectively.

◀ Fig 2. RBF map measured with ASL.