

UTE MRI investigation of a chronic asthma mouse model: quantification of peribronchovascular inflammation and correlation with airways hyperresponsiveness

Andrea Bianchi¹, Gerard Raffard², Olga Ousova¹, Annaïg Ozier¹, and Yannick Crémillieux¹

¹Centre de Recherche Cardio-Thoracique de Bordeaux, Université Bordeaux Segalen, Bordeaux, France, ²Centre de Résonance Magnétique des Systèmes Biologiques, Université Bordeaux Segalen, Bordeaux, France

Introduction:

Asthma is an increasingly prevalent disease whose main features are chronic bronchial inflammation, airways hyperresponsiveness (AHR) and remodeling [1]. Many studies have shown that important edematous inflammations can be quantified with the use of MRI in ovalbumin-challenged rats [2] but very limited work has been done on this important asthma model in mice [3]. All these studies involve the use of an OVA models with aluminum hydroxide (alum), which allows to get a significant edema in the lungs (easy to visualize and quantify with more or less standard acquisition sequences) but does not accurately reflect the slow development of the pathology in humans.

In this study we present the MRI investigation of a more realistic model of asthma (OVA without alum) [1], mimicking the first steps in the development of the disease in humans. The small peribronchovascular inflammation was visualized and quantified with the use of an Ultra-Short Echo Time (UTE) sequence and correlated with the enhanced pause (Penh) of the mice measured with a plethysmograph, an important and widely used means of quantification of AHR in mice.

Material and methods:

Protocol: Female Balb/c mice (6 weeks-old, 22 ± 0.3 g), purchased from Elevage Janvier (Le Genest, St Isle, France), were used for the experimentation. All the procedures were approved by the local Animal Care Committee. Six mice received an intraperitoneal injection of 100 μ g of ovalbumin (OVA) on Days 0 and 14 while the three control mice received an equivalent injection of saline solution. The mice received also an intranasal dose of 500 μ g of ovalbumin (OVA group) or saline (controls) on days 14, 27, 28 and 29, as described in Refs. [1] and [4]. The MR images were acquired on Days 0, before OVA/saline injection, and at day 34. The plethysmography was performed to all the animals on day 35.

MR acquisition: The images were acquired with a 4.7 T Biospec 47/50 spectrometer (Bruker, Ettlingen, Germany), using a transmitter/receiver quadrature coil of 25 mm inner diameter (Rapid Biomedical, Rimpfing, Germany). Mice were anesthetized with 2% isoflurane in a mixture of N₂/O₂ (80:20) via facial mask and placed supine in a custom-built plastic holder. The temperature was kept constant using warm circulating water and the respiratory cycle was constantly monitored. For each animal 12 consecutive axial slices of 1 mm thickness were acquired, in order to cover the whole lung volume. The acquisition was performed in *free-breathing* animals, using the 2D UTE sequence (804 directions/128 points, 4 averages), with a TR of 200 ms, TE of 276 μ s, FOV of 3 cm, FA of 30°, for a total acquisition time of about 10 minutes.

Image analysis: The images were reconstructed with in-house software implemented in IDL (RSI, Boulder, CO). The volume of the perivascular inflammation in the lungs was quantified with a semiautomatic segmentation procedure with the help of a medical image analysis software (MIPAV by JHU, US-MD). In particular, a low intensity threshold was applied to the images to exclude the healthy regions of the lung. The perivascular inflammation was contoured with a semiautomatic tool able to generate contours while moving over the different structures of the lung, recognizing the level of intensity of each pixel and selecting regions according to the pre-set parameters. Since the signal intensity due to the OVA-sensitization was comparable to the one produced by the vessel, a baseline was obtained at Day 0 before the beginning of the protocol. The computed volume (corresponding to the vessels) was subtracted to the one computed at Day 34 (corresponding to vessels and inflammation) after the OVA-challenge.

Plethysmography: The plethysmography was performed with a standard whole-body plethysmograph (Emka Technologies, Paris, France). For each mouse, the measurement was performed for 3 minutes for the basal respiration, the respiration after saline nebulisation (280 μ l) and after the nebulisation of a bronchoconstrictor (280 μ l of 8 mg/ml solution of methacholine). Penh values were computed for each breathing cycle and averaged over the 3 minutes measurements.

Results:

The images (Fig. 1) obtained with the UTE sequence, thanks to the ultra-short TE, allow the visualization of the signal produced by the parenchyma protons (the S/N in the lung parenchyma is about 30, with a resolution better than 300 μ m) with negligible motion artifacts. Consequently, such improvements over the typical lung images allow the visualization and quantification of the perivascular inflammation that characterize the OVA asthma model without alum. The average volume of inflammation measured in the OVA-challenged group (16.7 ± 2.7 μ l) and in the control mice (-0.3 ± 0.7 μ l) differs significantly in the two populations ($p < 0.012$). To evaluate the change in the AHR of the mice when challenged with saline and with methacholine, the ratio of the average Penh in the two cases has been computed. This index (7.4 ± 1.7 for the OVA group and 2.4 ± 0.5 for the controls) varies significantly in the two groups under examination ($p < 0.025$). A more careful analysis (Fig. 2) shows that the two parameters for all the mice are significantly correlated ($r = 0.74$, $p = 0.011$, $n=9$).

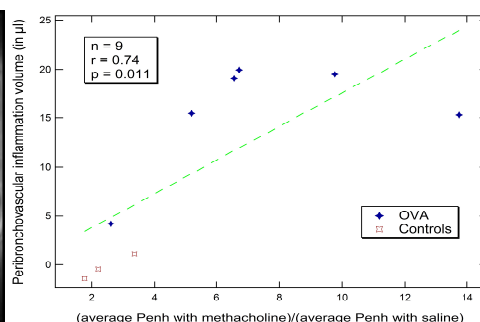
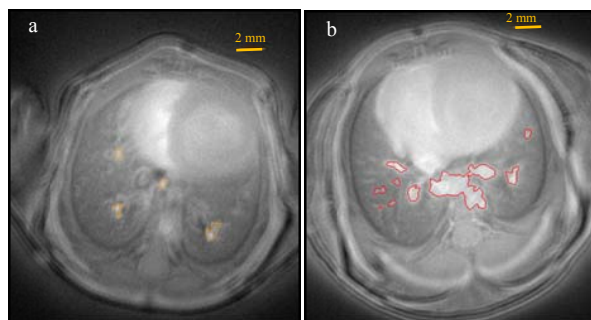


Fig 1. One of the 12 axial slices of an OVA group mouse taken at (a) Day 0 (with yellow contouring of the vessels) and (b) Day 34 (with red contouring of vessel and perivascular inflammation).

Fig 2. Correlation between the measured inflammation and the plethysmographic Penh index.

Discussion and conclusions:

This study demonstrates that the proposed MRI protocol is appropriate for the quantification of the small peribronchovascular inflammation typical of the OVA models without alum. The measured peribronchovascular inflammation, almost 3 times less than in the models with alum [3], well correlate with the quantification of the hyperresponsiveness, a very common and widely used lung functional parameter in biological studies. The two non-invasive techniques (MRI and plethysmography), altogether, offer a good characterization of the asthma model studied in this work and a proper assessment of the protocol described. The high quality of the images (signal to noise, spatial resolution and negligible motion artifacts) indicates the possibility of extending the protocol until the last phase of the OVA-model without alum, in order to assess the remodeling associated with the disease.

References:

- [1] *European Radiology*, 2010, 20, 128-137; [2] *Magn. Reson. Med.*, 2001, 45, 88-95;
- [3] *Radiology*, 2008, 248, 834-843; [4] *Am. J. Respir. Crit. Care Med.*, 2002, 165, 108-116

Acknowledgments: This work was supported by the European Marie Curie Action PI-NET-2010-264864