

## T2\* Measurements of 3 T MRI with Ultra-Short TE: Capability of Assessments for Pulmonary Functional Loss and Disease Severity in Patients with Connective Tissue Disease (CTD)

Yoshiharu Ohno<sup>1,2</sup>, Mizuho Nishio<sup>1</sup>, Hisanobu Koyama<sup>1,2</sup>, Masaya Takahashi<sup>3</sup>, Takeshi Yoshikawa<sup>1</sup>, Sumiaki Matsumoto<sup>1</sup>, Daisuke Takenaka<sup>1</sup>, Katsusuke Kyotani<sup>2</sup>, Nobukazu Aoyama<sup>2</sup>, Hideaki Kawamitsu<sup>2</sup>, Makoto Obara<sup>4</sup>, Marc van Cauteren<sup>5</sup>, and Kazuro Sugimura<sup>1</sup>

<sup>1</sup>Radiology, Kobe University Graduate School of Medicine, Kobe, Hyogo, Japan, <sup>2</sup>Radiology, Kobe University Hospital, Kobe, Hyogo, Japan, <sup>3</sup>Advanced Imaging Research Center, University of Texas Southwestern Medical Center, Dallas, Texas, United States, <sup>4</sup>Philips Electronics Japan, Tokyo, Japan, <sup>5</sup>Philips Healthcare Asia Pacific, Tokyo, Japan

**Introduction:** Involvement of the respiratory system is common in the connective tissue diseases (CTDs) and results in significant morbidity and mortality. Many of these diseases are characterized by the presence of a specific type of autoantibody, which may greatly assist specific diagnosis. Lung injury from CTD can affect each portion of the lung, the pleura, alveoli, interstitium, vasculature, lymphatic tissue, and both large and small airways. Most of the parenchymal manifestations of CTD are similar to those found in idiopathic interstitial pneumonias, and can be classified using the same system. Therefore, a careful evaluation of the chest radiograph and chest computed tomography (CT) in patients with parenchymal abnormalities can yield some useful clues to the presence of CTD. Currently, CT is most widely used for radiological assessment of severity in CTDs. Recently, we have tried to determine the utility of regional T2\* measurement in the lung for assessment of pulmonary diseases in animal studies (1, 2) and COPD subjects (3).

We hypothesized that direct T2\* measurement in the lung at 3 T MR system has a potential role to play as a method for pulmonary functional loss and disease severity assessments as well as thin-section MDCT in CTD patients. The purpose of this study was to determine the capability of pulmonary MRI with ultra-short TEs (UTES) in a 3 T system for pulmonary functional and disease severity assessments in patients with CTD.

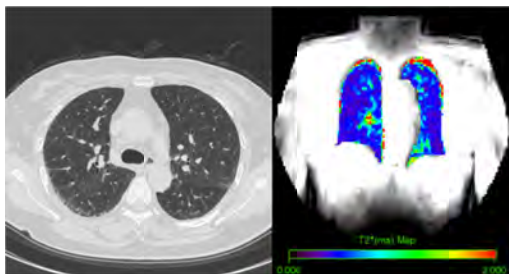
**Materials and Methods:** Eighteen CTD patients (8 men and 10 women; mean age 68 years) and 8 normal subjects who suspected chest disease (three men and five women; mean age 67 years) underwent thin-section MDCT at two 64- and a 320-detector row CT and pulmonary MR imaging with UTES (UTE MRI) at a 3T MR system. Serum KL-6 level and pulmonary function test (i.e. FEV<sub>1</sub>%, %VC and %DL<sub>CO</sub>) were also assessed in each subject.

All UTE MRI were obtained by using a 3D rephased radial sampling sequence with UTES (TR 10ms/ TE 0.2, 0.7, 1.2, 1.7, 2.2, 2.7, 3.2, 3.7, 4.2, 4.7 ms/ Flip angle 8 degree/ voxel size 3.52x3.52x3.52 mm/ 64x64 matrix, 128x128 reconstruction matrix, 1 NEX, 70 slices). The multi-echo UTE MR data were analyzed using the manufacture-provided software (Philips Electronics Japan), and mean T2\* value in the lung was calculated in each subject (3). Disease severity of CTD in each subject was determined from serum KL-6 level and semi-quantitatively assessed as CT-based disease severity by using visual scoring system according to past literatures (4).

To determine the difference of mean T2\* value between normal and CTD subjects, mean T2\* values in two groups were statistically compared by using Student's t-test. To assess the capability for pulmonary functional loss assessment and disease severity, mean T2\* value was statistically correlated with pulmonary functional parameters, serum KL-6 and CT-based disease severity including all subjects or only patients with CTD. A p value less than 0.05 was considered significant for all statistical analyses.

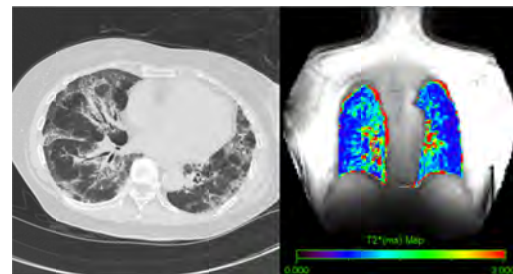
**Results:** Representative cases are shown in Figure 1 and 2. Mean T2\* value of normal subject (0.82±0.08 ms) was significantly shorter than that of CTD patient (1.08±0.20 ms, p<0.05). Results of correlation between mean T2\* value and pulmonary functional parameters in all subjects and patients with CTD are shown in Table 1. Mean T2\* value had significant, and moderate or fair correlations with all pulmonary functional parameters, serum KL-6 and CT-based disease severity (p<0.05). Mean T2\* value also had significant, and moderate or fair correlations with %VC, %DL<sub>CO</sub>, serum KL-6 level and CT-based disease severity (p<0.05).

**Conclusion:** UTE MRI on a 3T MR system was useful for assessments of pulmonary functional loss and disease severity in patients with CTD.



**Figure 1. Thin-section CT and T2\* map (L to R) in mild CTD patient.**

Thin-section CT demonstrates reticular shadows in the peripheries of lung, and CT-based disease severity is assessed as 9. T2\* map demonstrates heterogeneously and decreased T2\* values in the lungs. Mean T2\* value in this patient is 0.67±0.10 ms.



**Figure 2. Thin-section CT and T2\* map (L to R) in severe CTD patient.**

Thin-section CT demonstrated reticular shadows, traction bronchiectasis, volume loss in both lungs, and CT-based disease severity is assessed as 25. T2\* map demonstrates heterogeneously and markedly prolonged T2\* values in the lungs. Mean T2\* value in this patient is 1.40±0.12 ms.

**Table 1. Correlations between mean T2\* value and pulmonary functional parameters, serum KL-6 and CT-based disease severity in all subjects and only patients with CTD.**

		FEV <sub>1</sub> %		%VC		%DL <sub>CO</sub>		Serum KL-6		CT-based disease severity	
		r	p value	r	p value	r	p value	r	p value	r	p value
All subjects (n=26)	Mean T2* value	-0.40	0.04	-0.68	0.0001	-0.73	<0.0001	0.70	<0.0001	0.70	<0.0001
Only CTD patients (n=18)	Mean T2* value	-0.06	0.82	-0.53	0.02	-0.63	0.005	0.52	0.03	0.58	0.01

### References:

1. Takahashi M, Togao O, Obara M, et al. J Magn Reson Imaging. 2010;32(2):326-333.
2. Togao O, Tsuji R, Ohno Y, et al. Magn Reson Med. 2010;64(5):1491-1498.
3. Ohno Y, Koyama H, Yoshikawa T, et al. AJR Am J Roentgenol. 2011;197(2):W279-285.
4. Camiciottoli G, Orlandi I, Bartolucci M, et al. Chest. 2007;131(3):672-681.