

In Vivo Four-Dimensional Flow Analysis of Mechanically Assisted Ischemic Cardiomyopathy

Jeremy R. McGarvey^{1,2}, Walter R.T. Witschey^{2,3}, Kevin J. Koomalsingh², Norihiro Kondo², Manabu Takebe², Gerald A Zsido², Melissa M. Levack², Christen M. Dillard², Kristina Lau², Chun Xu², Francisco Contijoch², Alexander J. Barker⁴, Michael Markl⁵, Joseph H. Gorman^{1,2}, Robert C. Gorman^{1,2}, and James J. Pilla^{2,3}

¹Department of Surgery, University of Pennsylvania Health System, Philadelphia, PA, United States, ²Gorman Cardiovascular Research Lab, Harrison Department of Surgical Research, Glenolden, PA, United States, ³Department of Radiology, University of Pennsylvania Health System, Philadelphia, PA, United States, ⁴Department of Radiology, University Medical Center Freiburg, Freiburg, Germany, ⁵Department of Radiology, Northwestern University School of Medicine, Chicago, IL, United States

Introduction: Ischemic cardiomyopathy is associated with a multitude of chronic changes to the geometry, function, and biomechanics of the failing ventricle. Infarct expansion results in progressively enlarging adynamic or hypokinetic myocardium which can significantly alter the fluid dynamics within the ventricle. Early studies utilizing conductance catheter-based LV pressure-volume loops have shown that infarction raises the “zero-pressure volume” within the ventricle (i.e. V_0)—increasing the amount of functional dead space¹. Newer evidence from velocity-encoded 3D MRI also supports the formation of abnormal flow patterns within the left ventricle as the heart remodels—resulting in an increasing amount of retained blood within the ventricle (i.e. residual volume)². We have hypothesized that restoring or normalizing physiologic flow patterns may improve left ventricular mechanics and efficiency. While many invasive therapies have been described for the treatment of ischemic heart failure³, few have been designed to augment the left ventricular residual volume (or V_0) by directly changing the mechanics and geometry of the pathologic myocardium. As such, we have designed a novel MRI-compatible epicardial assist device that can actively alter the infarct V_0 in synchrony with remote myocardial contraction. Flow-sensitive 4D MRI was then performed *in vivo* following insertion of this device in a porcine heart failure model to assess infarct V_0 flow patterns during assist.

Methods: *Device Design* – An LV pressure-gated pulsation device was designed to rapidly inflate an implantable neoprene bladder using helium gas. The pulsation device may be positioned outside of the magnetic field to allow *in vivo* MRI while the device is active. An LV pressure transducer catheter (Millar Instruments, Houston, TX) is used to both gate the novel mechanical assist device and MRI.

Animal Model – Using a well-established model for ischemic cardiomyopathy, one Yorkshire swine weighing 40kg underwent ligation of the circumflex artery via thoracotomy. Twelve weeks post-infarction, the animal underwent directed placement of the assist device over the transmurally infarcted posterolateral epicardium.

in vivo MRI – Using a 3.0T Siemens MAGNETOM Trio A Tim MRI, 4D phase contrast MRI was safely performed during active mechanical assistance and with no assistance. 4D phase contrast pulse sequence parameters used for this acquisition were as follows: Venc=75cm/s, Spatial Resolution=2x2x2mm, Temporal Resolution=20.8ms.

Image analysis – 4D phase contrast processing included noise thresholding, velocity encoding aliasing removal, and eddy current corrections. Images were imported into computational fluid dynamics software (CEI Ensign, Apex, NC). Blood flow was computed from a plane parallel to the infarcted endocardial surface.




Figure 2: Systolic flow velocity mapping with (a) and without (b) mechanical assistance. Infarct denoted by arrow.

approximately 10cm/s, thereby eliminating intraventricular volume in proximity to adynamic myocardium (Figure 2). These findings are in stark comparison to the unassisted ventricle—where minimal flow is identified in this region throughout the cardiac cycle (Figure 3).

Discussion: Chronic adverse ventricular remodeling as a result of myocardial infarction has been shown to decrease the functional (ejected) volume within ventricle while increasing the residual volume and V_0 . We have successfully employed the use of a novel mechanical assist device to dramatically increase ventricular flow near the infarcted myocardium during both systole and diastole. By rapidly inflating the device in systole, the ventricular geometry not only changes, but blood volume with a predisposition to stagnation is forcibly moved from the adynamic endocardial surface to the contractile remote regions. During diastole, rapid deflation results in negative pressure being applied to the epicardial surface—which in turn augments local diastolic filling and flow via a suction effect. Our ability to change and quantify the flow profile of the failing ventricle using the novel mechanical assist device may in turn provide improved efficiency and function.

Acknowledgements: This research was supported by NIH R01-HL63954.

References: 1) Sunagawa et al. Circulation Research (1985);32:170-178. 2) Carlhäll, et al. Circ Heart Fail. (2010); 3:326-31. 3) George, T. J. et al. Prog Cardiovasc Dis. (2011);54,115-131.

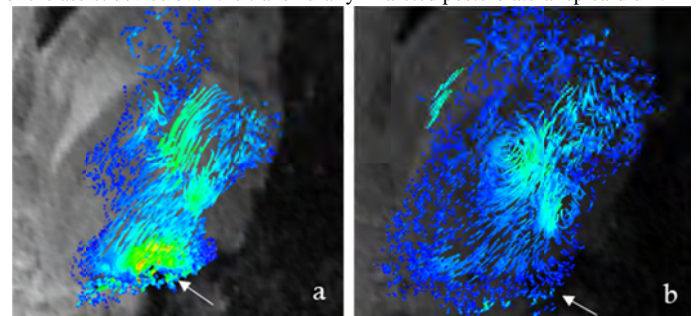


Figure 1: Diastolic flow velocity mapping with (a) and without (b) mechanical assistance. Infarct denoted by arrow.

Results: *In vivo* 4D phase contrast MRI was successfully acquired with and without active mechanical assistance. When compared with the unassisted state, flow patterns near the assist device were significantly altered in both systole and diastole. During early diastolic filling, rapid deflation of the device creates a local intraventricular negative pressure gradient—resulting in flow velocities over 15cm/s towards the ventricular wall (Figure 1). Conversely during early systole, rapid device inflation creates an extrinsic force to redistribute blood away from the infarct at

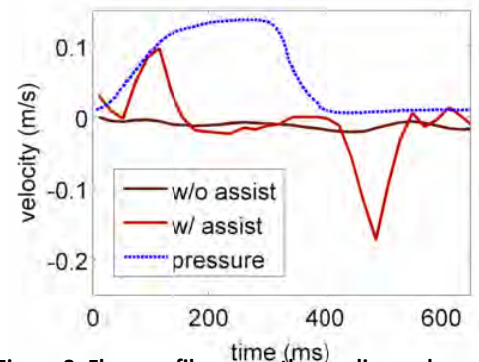


Figure 3: Flow profile across the cardiac cycle with and without mechanical assistance.