

Comparison of Diagnostic Image Quality of HYPR and TRICKS for Peripheral MRA Exams in Patients

Lauren Keith¹, Mark Schiebler², Chris Francois², Scott Reeder^{2,3}, and Frank Korosec^{1,2}

¹Medical Physics, University of Wisconsin-Madison, Madison, WI, United States, ²Radiology, University of Wisconsin-Madison, Madison, WI, United States,

³Biomedical Engineering, University of Wisconsin-Madison, Madison, WI, United States

Introduction: In the United States, peripheral vascular disease (PVD) has an estimated prevalence of 4.3% (95% CI: 3.1-5.5%) in individuals >40 years of age and is an important cause of morbidity [1]. Currently, non-invasive diagnostic imaging (CTA or MRA) is used to plan for both surgical and percutaneous treatment of PVD. MRA has an advantage over CTA for showing complex collaterals in the peripheral vasculature and it is insensitive to calcium. Challenges for MRA of the peripheral vasculature include the need for high spatial and temporal resolution. There are two limitations of time-resolved imaging [2] as it is currently used in MRA for PVD. First, there is limited, non-isotropic spatial resolution >1.0 mm. Second, there is low temporal resolution that can lead to diagnostic challenges due to venous contamination before slower filling collaterals enhance. To overcome these limitations, methods with improved temporal and spatial resolution are needed. In this clinical investigation, we compare the diagnostic image quality of a method with high spatial and temporal resolution (VIPR-HYPR) [3] with TRICKs using Digital Subtraction Angiography (DSA) as a reference standard. We hypothesize that VIPR-HYPR will provide similar or better image quality than TRICKs and that the improved temporal and spatial resolution will provide increased diagnostic confidence for patients with PVD.

Methods: Six patients (with an eGFR > 30.0 ml/min/1.73m²) scheduled for a DSA were recruited for this study. MRA research exams were conducted prior to the DSA. The research MRA protocol was performed on a 3T MR750 scanner with a 32-channel phase array abdominal coil (GE Healthcare, Waukesha, WI, USA) and consisted of two exams: TRICKs and VIPR-HYPR. The order of the exams was randomized. Each acquisition was performed with 0.05 mmol/kg of contrast material (MultiHance, Bracco Diagnostics, USA) administered at a rate of 2.5-3.0 ml/s. Imaging parameters for the TRICKs exam were similar to those used clinically at our institution, but also included ASSET parallel imaging (not used clinically). Image parameters for TRICKs include: 400 x 320 x 124 mm FOV; 1.25 x 1.25 x 2.0 mm spatial resolution; FA: 25°; TE/TR: 1.3ms/3.832ms; BW: ±83.88kHz; frame update rate: 6.1 s, parallel imaging acceleration R=2 in the L/R direction. VIPR-HYPR imaging parameters include: 400 mm isotropic FOV; 1.0 mm isotropic spatial resolution; FA: 20° TE/TR: 1.3ms/4.2-4.5ms; BW: ±125.0kHz; HYPR weighting image temporal resolution: 4.7 – 5.6 s; HYPR composite image acquisition duration: 154 – 192 s. DSA exams were performed by experienced vascular surgeons on a Phillips INTEGRIS V system using the typical clinical protocol. Note that while MRA images were collected bi-laterally - for DSA, images of only a single leg were obtained.

Results and Discussion: Figure 1 shows a comparison of the MRA methods used in this study. TRICKs and VIPR-HYPR arterial MIPs are shown along with sagittal MIPs of a single leg. The improved spatial resolution of the VIPR-HYPR method can be appreciated. MRA and DSA results from two patients are shown in Figures 2 and 3; in both figures, MRA MIPs are cropped and enlarged to match the FOV of the DSA image. Note that disease and stenoses seen in the DSA images are also visible in the VIPR-HYPR MIPs. See figure captions for detailed discussions of these results.

Conclusion: The VIPR-HYPR method provides higher spatial and temporal resolution images than current clinical time-resolved MRA techniques and accurately depicts disease in patients with PVD.

Acknowledgments: We gratefully acknowledge GE Healthcare for contributing research support to this project. This project was funded by NIH grant R01EB006882.

References: [1] Selvin E, *et al.* Circulation. 2004;110:738-743. [2] Keith LA, *et al.* Procs 18th ISMRM, 2010 #1418. [3] Korosec, *et al.* MRM.1996;36:345-351.

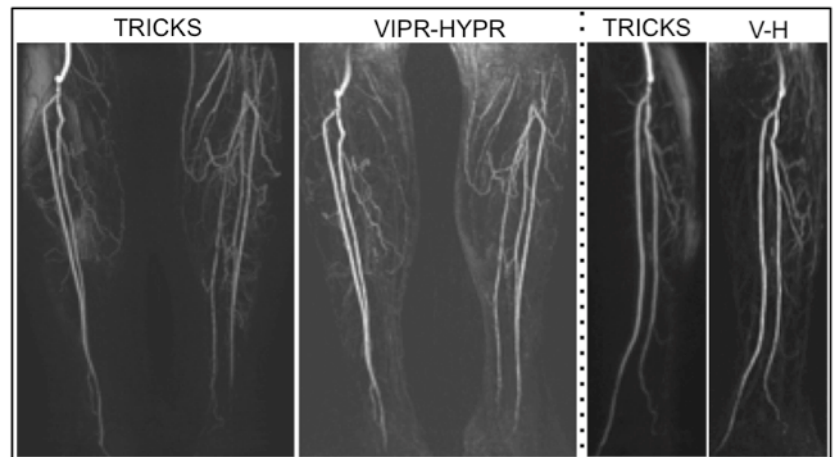


Figure 1: Coronal MIPs of arterial time frames from TRICKs and VIPR-HYPR exams of a patient. Sagittal MIPs of the patients right leg from TRICKs and VIPR-HYPR (V-H) exams exemplify the decreased spatial resolution in the slice direction of the TRICKs protocol. The isotropic spatial resolution of VIPR-HYPR can easily be appreciated.

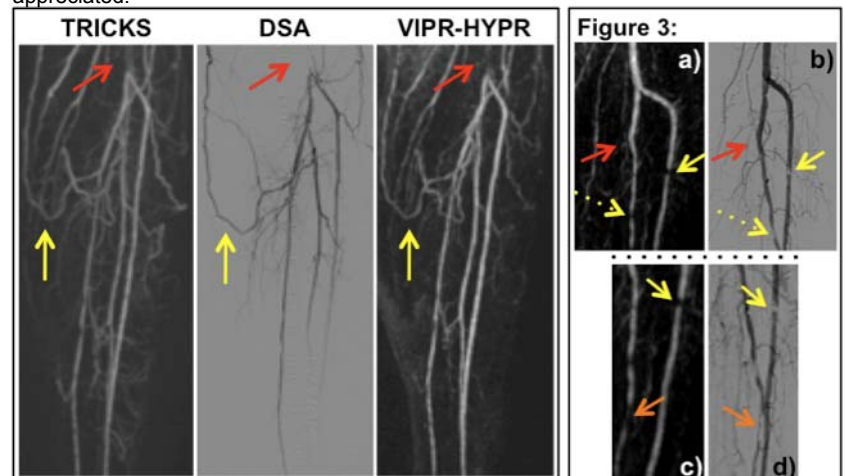


Figure 2: Enlarged segments of arterial time frame coronal MIPs from TRICKs and VIPR-HYPR exams of a patient are shown in comparison with the DSA image of the same anatomy. The occlusion of the popliteal artery (red arrow) is clearly visualized in all three images as well as the collateral vessel (yellow arrow) filling the vasculature distal to the occlusion. The increased spatial resolution in the coronal plane [1.25 x 1.25 mm for TRICKs vs. 1.0 x 1.0 mm] of the VIPR-HYPR exam is apparent.

Figure 3: Comparison of corresponding vessel segments from the VIPR-HYPR (a c) and DSA (b d) exams for a different patient. Note the occlusion of the posterior tibial artery (red arrow) in a) and b) as well as the stenoses (yellow arrows). A slightly distal FOV is shown in c) and d). (Note the stenosis marked by the solid yellow arrow in c) and d) is the same stenosis in a) and b) marked with the solid yellow arrow).